

Oral medicine case book 52: Pleomorphic adenoma of the upper lip

SADJ August 2013, Vol 68 no 7 p328 - p330

S Stander¹, S Mulder-Van Staden², T Y Cheung³, WP Dreyer⁴, N Mohamed⁵, A Afrogheh⁶

CASE REPORT

A 46-year old female presented at the Oral Medicine Clinic complaining of a large and painless swelling of her upper lip. The lesion had slowly enlarged over the past year and was causing an increasing aesthetic and speech impairment. Her medical history revealed nothing of note. Extra-orally, the patient presented with a swelling involving the right side of the upper lip and extending from the right alar of the nose, to the right commissure (Figure 1). The intra-oral examination revealed a firm and well circumscribed mass in the upper right labial mucosa, opposite the upper second incisor, canine

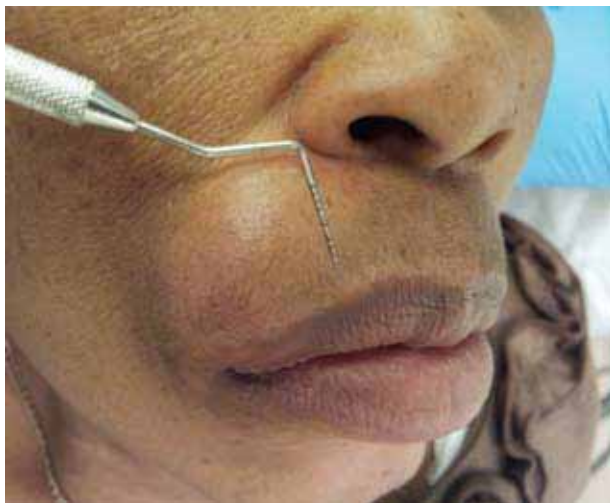

Figure 1: The swelling on the upper lip extended from beneath the right alar of the nose towards the right corner of the mouth and was approximately 2x3 cm in size.

1. **S Stander:** *BChD, PDD*, Division of Oral Medicine and Periodontics, Faculty of Dentistry, University of the Western Cape.
2. **S Mulder-Van Staden:** *BChD*, Division of Oral Medicine and Periodontics, Faculty of Dentistry, University of the Western Cape.
3. **T Y Cheung:** *BChD, PDD*, Division of Oral Medicine and Periodontics, Faculty of Dentistry, University of the Western Cape.
4. **WP Dreyer:** *BDS, HDipDent, PhD, FCD(SA)OMP*, Division of Oral Medicine and Periodontics, Faculty of Dentistry, University of the Western Cape; Professor Emeritus, Stellenbosch University.
5. **N Mohamed:** *MBChB, MMed(Anat Path)*, Division of Anatomical Pathology, Department of Pathology, University of Stellenbosch; National Health Laboratory Service, Tygerberg.
6. **A Afrogheh:** *BChD, MChD*, Division of Oral Pathology, Faculty of Dentistry, University of the Western Cape; National Health Laboratory Service, Tygerberg.

Corresponding author

WP Dreyer:

PO Box 1285, Sedgefield, 6573; e-mail wpd@sun.ac.z,

ACRONYM

FNAB: fine needle aspiration biopsy

and first premolar. The mass was approximately 2x3 cm in size and the overlying mucosa was of normal consistency and colour for the region (Figure 2). A fine needle aspiration biopsy (FNAB) of the mass was performed (Figure 3). During the aspirate, the lesion felt mobile and encapsulated and

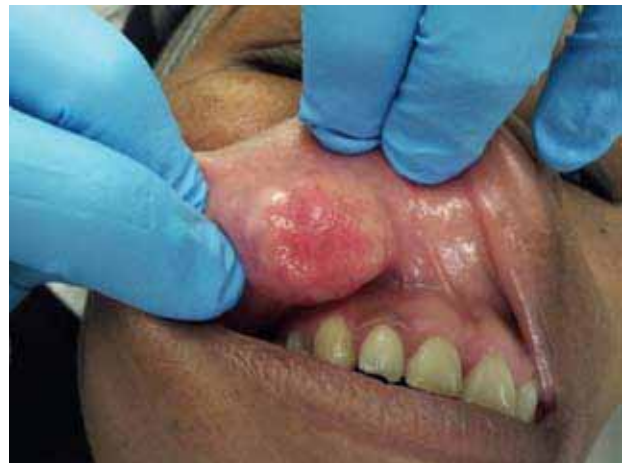

Figure 2: The swelling in the right upper lip was found to be a firm and well-circumscribed mass with the overlying tissues revealing normal colour and consistency.

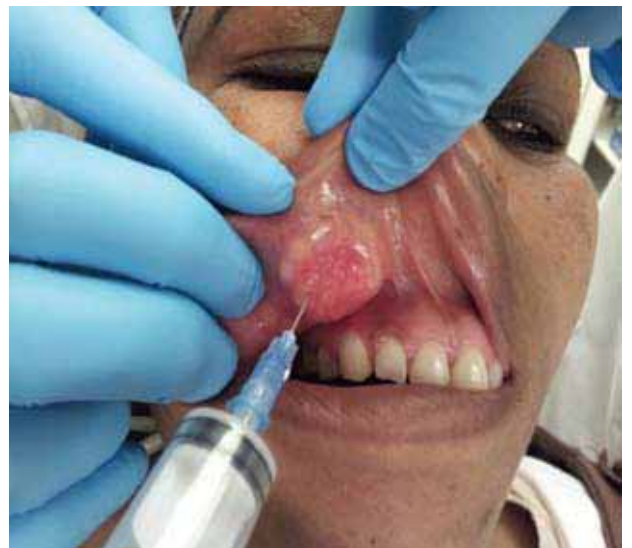

Figure 3: A fine needle aspiration biopsy of the mass was performed and the aspirate sent for cytological evaluation.

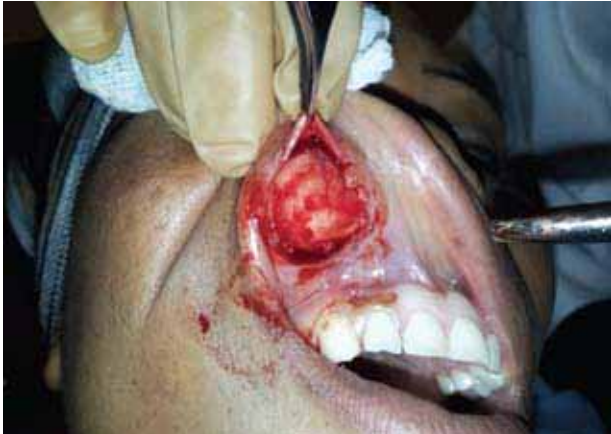

Figure 4: This view of the surgically exposed mass shows its well-circumscribed nature and the presence of minor salivary glands at the periphery of the incision.

was thought to be clinically benign. Therefore an excisional biopsy was performed immediately after the FNAB (Figure 4). A 0.2% aqueous solution of chlorhexidine digluconate was prescribed as an antibacterial mouthwash and the patient instructed to return in two weeks for suture removal and further therapy, should it be necessary.

DIAGNOSIS AND MANAGEMENT

On the basis of the clinical features and symptoms, a preliminary diagnosis of a benign salivary gland tumour was made. The aspirate taken from the FNAB showed the pres-

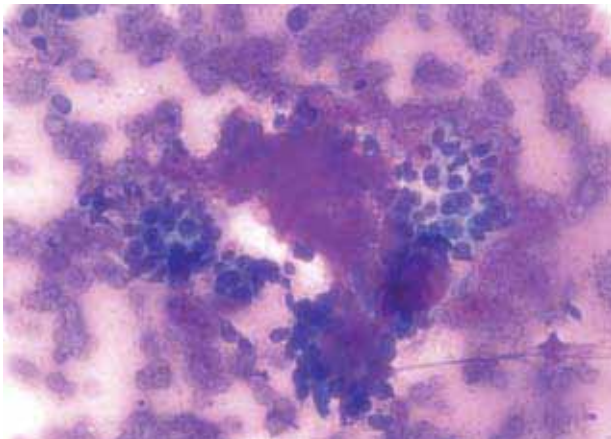


Figure 5: Cytology of the aspirate obtained by FNAB. Plasmacytoid myoepithelial cells (blue) are seen associated with a pink fibrillar metachromatic material. Giemsa stain, x40.

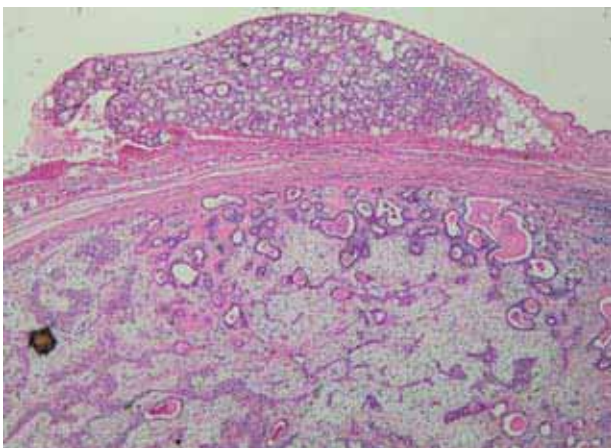


Figure 6: This histopathology slide shows the tumour to be well circumscribed and invested in a thick fibrous capsule. Note the adjacent normal minor salivary gland tissue, H&E, x10.

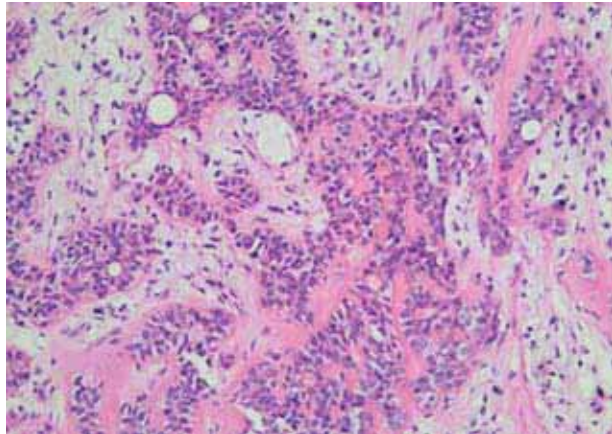


Figure 7: The tumour consisted of small duct-like structures lined by an inner layer of eosinophilic ductal cells and an outer layer of myoepithelial cells which disperses into the surrounding chondromyxoid stroma. The myoepithelial cells are intimately associated with a pink acellular fibrillar material, H&E x40.

ence of ductal and myoepithelial-like cells in a metachromatic fibrillary background, compatible with a pleomorphic adenoma (Figure 5). The histological evaluation revealed the lesion to be well circumscribed and encapsulated. The mass was composed of epithelial and myoepithelial cells within a chondromyxoid stroma. Squamous differentiation was also visible (Figures 6 and 7). A final diagnosis of pleomorphic adenoma of a minor salivary gland was made and it was confirmed that the margins of the mass were clear. In view of the total removal of the tumour, no further management was considered to be necessary.

DISCUSSION

Pleomorphic adenoma, also known as benign mixed tumour, is a benign salivary gland tumour that exhibits a wide cytological and morphological diversity. It consists of epithelial, myoepithelial and stromal components. A wide range of histological presentations is possible, due to the varying expression of the different elements and for that reason, the adjective "pleomorphic" was coined for this adenoma. However, it should be noted that this refers to the neoplasm's architectural rather than to its cellular pleomorphism.¹

Salivary gland neoplasms, in general, are relatively uncommon and mostly affect the major salivary glands, primarily the parotid gland. Neoplasms of the minor salivary glands are encountered even less often and reportedly represent 9-23% of all salivary gland neoplasms.¹ Pleomorphic adenoma is the most common neoplasm originating from cells of the salivary glands and most frequently presents in the parotid gland.^{1,2,3} It accounts for approximately three quarters of all benign neoplasms of the salivary glands and typically occurs in the fifth and sixth decades of life.^{4,5} In two case studies published in South Africa, pleomorphic adenoma was also the most common tumour seen in minor salivary glands with a reported frequency of 72% and 48% respectively.^{6,7}

The aetiology of pleomorphic adenoma is not clear, however, it is essentially epithelial in nature and clonal chromosome irregularities, with abnormalities involving 8q12 and 12q15, have been reported.^{5,8} It has been recorded that the incidence of the tumour increases 15 to 20 years after exposure to radiation and, in addition, it has been suggested that infection with the simian virus (SV40) may play a role.⁴

Pleomorphic adenoma presents clinically as a slow-growing, painless and firm mass. It is a solitary, nodular, mobile

and well-circumscribed lesion covered by healthy mucosa.⁸ If neglected, it can grow to large dimensions. The neoplasm not only mostly affects the parotid gland but, for an unknown reason, right side involvement of the superficial lobe is more common.⁴ In this instance it presents as a well-circumscribed, pre-auricular swelling. If, however, the neoplasm originates elsewhere in the parotid gland, it may present as a cheek swelling or a bucco-masseteric mass. When affecting the submandibular gland, the neoplasm tends to present as a swelling under the angle of the mandible, whereas sublingual gland involvement is seen as a swelling in the floor of the mouth.

Minor salivary gland involvement accounts for approximately 40% of all pleomorphic adenomas and may affect any area in the upper aero-digestive tract and para-pharyngeal fat spaces. Intra-orally, the most common site is the junction of the hard and soft palate, followed by the lip. Pleomorphic adenomas may also appear in unusual sites such as the sinuses, larynx, epiglottis and trachea. If these areas are affected, symptoms may include dyspnoea, dysphagia, acute airway obstruction and obstructive sleep apnoea. Other tissues with glandular tissue may also, rarely, be involved and may include unlikely sites such as the lacrimal glands and vulva.¹

Of the three cellular components,^{2,4} both epithelial and mesenchymal elements must be present for a diagnosis. The expression of these components vary amongst the different histological sub-types. This benign neoplasm is usually confined by a fibrous capsule when it arises in the major salivary glands, however, the capsule may be partially or completely absent when this neoplasm presents in the minor salivary glands. Cells of glandular epithelial origin give rise to ductal or cystic structures. The myoepithelial cells have many cytological appearances (epithelioid, spindle, plasmacytoid or clear cells) and are responsible for the mesenchymal-like changes (myxoid, hyaline, cartilaginous and osseous structures) which characterises the background of the lesion.^{1,2}

The clinical presentation of pleomorphic adenoma may be quite diverse and therefore may present a diagnostic challenge. The differential diagnosis of any asymptomatic solitary mass, or swelling in the oral cavity, should include a minor salivary gland neoplasm, a lipoma and a benign or malignant mesenchymal lesion such as neurofibroma and rhabdomyosarcoma.⁵ Clearly, a biopsy and histopathological assessment is needed before a final diagnosis can be reached, but it is a wise precaution to employ additional diagnostic aids before resorting to biopsy. A variety of additional techniques are available to the clinician, including ultrasound, computerised tomography and magnetic resonance imaging. However, these techniques may be out of reach in many clinical settings and it is therefore suggested that fine needle aspiration biopsy be employed. The primary aim of FNAB is to determine the presence or absence of neoplastic tissues and to diagnose the neoplasm as either benign or malignant. The technique is relatively simple and minimally invasive and provides a high level of diagnostic accuracy (up to 97%).¹¹ Clinicians should receive training in the procedure to ensure consistent specimens of good diagnostic quality. This will help to minimise problematic cases where there is an approximately 3% possibility of a false negative for malignancies.^{11,12} As some 50% of all neoplasms originating from the minor salivary glands are reported to be malignant, this seemingly low false positive does pose a risk.¹ Furthermore, with FNAB, there is the concern of recurrence of mixed neoplasms and of spreading the tumour cells along the track of the needle.^{11,12}

The ideal management of a pleomorphic adenoma is wide surgical excision with clean margins. If the neoplasm occurs in the parotid gland, then a superficial or total parotidectomy can be performed with careful preservation of the facial nerve.^{1,9} If the neoplasm originates in the minor salivary glands of the palate, buccal mucosa or lip, wide surgical excision is essential as the neoplasm in these sites typically lacks a fibrous capsule and may grow out into the surrounding normal host tissue. Inadequate surgical excision may result in capsular penetration, or rupturing of the neoplasm with spillage of tumour cells into the normal host tissue. In addition, any pseudopodia remaining after surgery, may also predispose to recurrence of the neoplasm, possibly explaining the reported recurrence rate of 2% to 44%.^{5,10} This endorses the importance of periodic follow-up of patients. It should also be remembered that, on occasion, pleomorphic adenoma may undergo malignant transformation and may give rise to carcinoma ex-pleomorphic adenoma or carcinosarcoma.⁸

CONCLUSION

Minor salivary gland lesions in the oral cavity are reasonably common and can cause the patient concern and limit normal function, particularly when large lesions appear on the lips such as in the case presented above. Fortunately, most are benign in nature, but the clinician must use all diagnostic information available, before resorting to removal in order to avoid surgical complications. In this respect FNAB may be a useful diagnostic technique and it is suggested that clinicians be routinely trained in its use. The present case also demonstrated the use of FNAB as a useful screening test in the establishment of the diagnosis.

Declaration: No conflict of interest declared.

References and recommended reading*

- *Lingam RK, Dagher AA, Nigar E, *et al.* Pleomorphic adenoma (benign mixed tumour) of the salivary glands: its diverse clinical, radiological and histopathological presentation. *Brit J of Oral Maxillofac Surg* 2011; 49: 14 – 20.
- Reddy M, Mahajan B, Chandwani R, *et al.* A case of pleomorphic adenoma of upper lip. *Indian J Stomatol* 2012; 3: 129-31.
- *Jaber MA. Intraoral minor salivary gland tumours: a review of 75 cases in a Libyan population. *Int J Oral Maxillofac Surg* 2006; 35: 150-4.
- Melkundi M, Babaji P, Saikhedkar R, Chaluvaiiah MB. Pleomorphic adenoma of parotid gland: a case report. *Oral Maxillofac Pathol J* 2012; 3: 228-31.
- Lotufo MA, Júnior CAL, de Mattos JP, Franca CM. Pleomorphic adenoma of the upper lip in a child. *J Oral Sci* 2008; 50: 225-8.
- Isacsson G, Shear M. Intraoral salivary gland tumors: a retrospective study of 201 cases. *J Oral Pathol* 1983; 57-62.
- Van Heerden WF, Raubenheimer EJ. Intraoral salivary gland neoplasms: a retrospective study of seventy cases in an African population. *Oral Surg Oral Med Oral Pathol* 1991; 71: 579-82.
- Iqbal A, Gupta AK, Singh S. Pleomorphic adenoma of the upper lip. *National J Maxillofac Surg* 2011; 2: 219-21.
- Kuo Y-L, Tu T-Y, Chang C-F, Li W-Y, *et al.* Extra-major salivary gland pleomorphic adenoma of the head and neck: a 10-year experience and review of the literature. *Eur Arch Otorhinolaryngol* 2011; 268: 1035-40.
- Nouraei SAR, Ferguson MS, Clarke PM, *et al.* Metastasizing pleomorphic salivary adenoma. *Arch Otolaryngol Head Neck Surg* 2006; 132: 788-93.
- *Boccardo P, Altavilla G, Blandamura S. Fine needle aspiration biopsy of salivary gland lesions. A reappraisal of pitfalls and problems. *Acta Cytol*, 1998; 42: 888-98.
- Jung Jo H, Jung Ahn H, Jung S, Yoon H-K. Diagnostic difficulties in fine needle aspiration of benign salivary glandular lesions. *Korean J Pathol* 2012; 46: 569-75.