

# **Correlating the Intra-Operative position of the Inferior Alveolar Nerve with Pre-Operative Cone- Beam Computer Tomography in Bilateral Sagittal Split Osteotomies**

**Mark Keith Meyer**



A mini-thesis submitted in partial fulfilment of the requirements for  
the degree of MChD in the Department of Maxillo-Facial and Oral  
Surgery, University of the Western Cape

Supervisor


Prof J A Morkel

# TABLE OF CONTENTS

Title Page	1
Table of Contents	2
Declaration	5
Dedication	6
Acknowledgements	7
List of Abbreviations	8
Keywords	9
Abstract	10
List of Tables	11
List of Figures and Charts	12
List of Appendices	13
CHAPTER 1	14
Introduction	14
CHAPTER 2	15
Literature review	15
2.1 History of Bilateral Sagittal Split Osteotomy	16
2.2 Advantages of the Bilateral Sagittal Split Osteotomy	17
2.3 Neurosensory Impairment as a Complication of Bilateral Sagittal Split Osteotomy	17
2.4 Techniques to identify the Inferior Alveolar Nerve	18
2.4.1 Identifying the Inferior Alveolar Nerve using Anatomical Specimens	18
2.4.2 Identifying the Inferior Alveolar Nerve using Two-dimensional Images	19
2.4.3 Reliability of Anatomical Specimens and Two-dimensional Images when identifying the Inferior Alveolar Nerve	19
2.4.4 Identifying the Inferior Alveolar Nerve using Cone Beam Computer Tomography	20



CHAPTER 3	23
Research Design and Methodology	23
Aim	23
Objectives	23
Study Design	24
Study population	24
Inclusion criteria	24
Exclusion criteria	24
Anaesthetic technique	25
Surgical technique	25
Pre-surgical imaging and planning	27
Post-operative management	32
Criteria to be evaluated	32
Data management and statistical analysis	32
Ethical statement	33
CHAPTER 4	34
Results	34
4.1 Demographic information and procedure type	34
4.2 Intra-operative identification of the inferior alveolar nerve	34
4.3 Measured distance between the inferior alveolar canal and the mandibular cortices	35
4.3.1 Distance between the inferior alveolar canal and buccal cortical bone	35
4.3.2 Distance between the inferior alveolar canal and lingual cortical bone	35
4.3.3 Distance between the inferior alveolar canal and inferior cortical bone	36
4.3.4 Distance between the inferior alveolar canal and superior cortical bone	36
4.4 Mean distance between the inferior alveolar canal and mandibular cortices	37
4.4.1 Mean distance between the lingual cortical bone and inferior alveolar canal	37
4.4.2 Mean distance between the inferior cortical bone and inferior alveolar canal	37
4.4.3 Mean distance between the superior cortical bone and inferior alveolar canal	37
4.4.4 Mean distance between the buccal cortical bone and inferior alveolar canal	37
4.4.5 Procedure type compared with nerve manipulation	38
4.4.6 Mean distance between the inferior alveolar canal and buccal cortical bone compared to procedure type	38



CHAPTER 5	39
Discussion	39
Conclusion	43
References	44
Appendix I: Data capture sheet	47
Appendix II: Patient information letter	48
Appendix III: Informed consent	49



# DECLARATION

I declare that *Correlating the intra-operative position of the inferior alveolar nerve with pre-operative cone-beam computer tomography in bilateral sagittal split osteotomies* is my own work, that it has not been submitted for any degree or examination at any other university, and that all the sources I have used or quoted have been indicated and acknowledged by complete references.

Full name: Mark Keith Meyer

Date.....

Signed.....



## DEDICATION

*To my wife, Joann, and my children, Gary and Declan, for their unwavering love, support, patience and understanding during the last few years. To my parents, Agnes and Stephen Meyer, for raising and believing in me, and helping me realise this achievement. I wish to thank them for instilling discipline and motivation to do my best at all times. Thank you to my sister, Dr Anstea Meyer, for all her support.*



## ACKNOWLEDGEMENTS

### *I would like to thank:*

My Supervisor, Professor J A Morkel, for his expertise, guidance and support – you have been a shoulder to rely on – without you this work would not have seen the light of day.

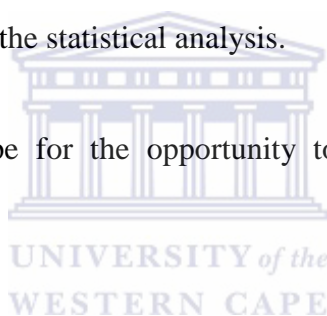
Sincere thanks goes to Prof G Kariem and Dr G Hein, for all the guidance over the last five years. Thank you to all the consultants that were part of my training the past few years.

Thank you to my fellow registrars for their support - it was a privilege training with such a good team.

I would like to acknowledge all the auxiliary staff of the Maxillo-Facial and Oral Surgery department at Groote Schuur, Tygerberg and Red Cross Children Hospitals.

Dr D Smit for his assistance with the statistical analysis.

The University of Western Cape for the opportunity to study Maxillo-Facial and Oral Surgery.



## LIST OF ABBREVIATIONS

IAN:	Inferior Alveolar Nerve
CBCT:	Cone Beam Computer Tomography
BSSO:	Bilateral Sagittal Split Osteotomy
NSI:	Neurosensory Impairment
IAC:	Inferior Alveolar Canal
CT:	Computer Tomography
SSRO:	Sagittal Split Ramus Osteotomy
SSO:	Sagittal Split Osteotomy
MMF:	Maxillomandibular Fixation
ICU:	Intensive Care Unit
UWC:	University of Western Cape
OPS:	Operation Sites
BCB:	Buccal Cortical Bone
LCB:	Lingual Cortical Bone
ICB:	Inferior Cortical Bone
SCB:	Superior Cortical Bone
X:	Lingula
Y:	Midpoint between Lingula and Second Molar
Z:	Distal to Second Molar





## **KEYWORDS**

Bilateral Sagittal Split Osteotomy

Sagittal Split Osteotomy

Inferior Alveolar Nerve

Cone Beam Computer Tomography

Mandible

Complications

CBCT

Neurosensory Impairment



## ABSTRACT

**Aim:** The aim of the study was to investigate whether a correlation exists between the intra-operative position of the Inferior Alveolar Nerve (IAN) and the nerve position as noted on a pre-operative Cone Beam Computer Tomography (CBCT) scan in patients requiring Bilateral Sagittal Split Osteotomy (BSSO) of the mandible.

**Introduction:** The BSSO of the mandible is of fundamental importance in the correction of dental facial deformities. The main post-operative complication of a BSSO of the mandible is Neurosensory Impairment (NSI). To avoid possible NSI it is important to have as much pre-operative information as possible. In this regard, pre-operative CBCT scans can provide the surgeon with an important assessment of the mandibular canal. This information on the buccolingual, superior and inferior position of the canal, especially in the region of the planned osteotomy, could help the surgical team to avoid IAN injury.

**Materials and Methods:** This study correlates the pre-operative position of the IAN as indicated on a CBCT scan with the intra-operative IAN position in patients requiring BSSO of the mandible. Ten standardised cases were included in a prospective case series where twenty mandibular sides were assessed.

**Results:** The variables assessed in this study were location of the nerve, age, sex, type of movement and side of mandible operated on. It was found that only the distance between the Inferior Alveolar Canal (IAC) and the lower border of the mandible are predictive of whether the IAN will be attached to - or free from - the proximal segment of the mandible.

**Conclusion:** From the study it can be concluded that a CBCT scan is a useful and reliable modality in the pre-operative evaluation of patients undergoing BSSO especially with regard to the assessment and mapping of the mandibular canal.

## LIST OF TABLES

Table 1:	Demographic information and procedure type
Table 2:	Distance between inferior alveolar canal and buccal cortical bone
Table 3:	Distance between inferior alveolar canal and lingual cortical bone
Table 4:	Distance between inferior alveolar canal and inferior cortical bone
Table 5:	Distance between inferior alveolar canal and superior cortical bone
Table 6:	Mean distance between the inferior alveolar canal and the outer cortex at point X, Y and Z



## LIST OF FIGURES AND CHART

Fig 1: Orthopantomogram 12 mm in thickness

Fig 2: Orthopantomogram 0.3 mm thick for identification of inferior alveolar canal

Fig 3: Identification of inferior alveolar canal

Fig 4: Identification of inferior alveolar nerve left and right side of mandible

Fig 5: Orthopantomogram 10 mm thick with identification of inferior alveolar nerve

Fig 6: Cross-sectional cuts from lingula to distal aspect of second molar

Fig 7: Inferior alveolar nerve as it enters the inferior alveolar canal

Fig 8: Cross-section at the level of the lingula with measured values of the medullary bone present at the lingula

Fig 9: Cross-section midpoint between the lingula and distal part of second molar

Fig 10: Cross-section distal to second molar

Fig 11: Surgybone<sup>®</sup>

Fig 12: Measured distances from the inferior alveolar canal to mandibular cortex

Fig 13: A Inferior alveolar canal in contact with buccal and lingual cortex  
B Inferior alveolar canal in contact with lingual cortex with minimal medullary bone present  
C Inferior alveolar canal present with no medullary bone present

## **LIST OF APPENDICES**

Appendix I: Data capture sheet

Appendix II: Patient information letter

Appendix III: Consent form



# CHAPTER 1

## INTRODUCTION

Osteotomies of the mandible are important treatment modalities in the correction of dental facial deformities. Currently Bilateral Sagittal Split Osteotomy (BSSO) is considered the benchmark in treating mandibular asymmetries, mandibular prognathism and retrognathism (Westermarck et al., 1998).

The main post-operative complication of the BSSO of the mandible is Neurosensory Impairment (NSI) (Yamauchi et al., 2012). Pre-operative information regarding potential NSI should be examined in as many formats possible (Lee et al., 2011). This includes medical images as they are an important means of assessing the risk of complications and improving the doctor-patient relationship. In this regard a Cone-beam Computer Tomography (CBCT) scan is an important part of the surgeon's pre-operative assessment of the mandibular canal (Lee et al., 2011). Information on the buccolingual, superior and inferior position of the canal, especially in the region of the planned osteotomy, could assist surgeons in avoiding injury to the Inferior Alveolar Nerve (IAN) (Nakagawa et al., 2003).

## CHAPTER 2

### LITERATURE REVIEW

Bilateral Sagittal Split Osteotomy (BSSO) is considered as the benchmark in the treatment of mandibular asymmetries, mandibular prognathism and mandibular retrognathism. The main post-operative complication of the BSSO of the mandible is Neurosensory Impairment (NSI). This can be due to direct or indirect injury to the Inferior Alveolar Nerve (IAN) (Panula et al., 2001). Indirect injury to the IAN may result from post-operative oedema or haematoma. Direct damage to the IAN may occur during the osteotomy by surgical instruments including retractors, burs, chisels or miniplate osteosynthesis.

The IAN is most vulnerable during the splitting procedure. The nerve can either be adherent to the distal or proximal segment of the mandible. If the IAN is attached to the proximal segment of the mandible, it needs to be released. Attempts to release the nerve from the proximal segment of the bone can cause direct injury to the nerve or disrupt the vascular supply causing ischaemic injury to the nerve.

The incidence of NSI as a result of a BSSO procedure ranges from 13% to 100% immediately after surgery and 0% to 85% 1-2 years post-surgery (August et al., 1998, Fridrich et al., 1995, Nakagawa et al., 2003, Panula et al., 2001, Takeuchi et al., 1994, Westermarck et al., 1998, Wittwer et al., 2012, Yamauchi et al., 2012, Ylikontiola et al., 2000, Yoshida et al., 1989).

When NSI is present, the patient will complain of various degrees of numbness of the lower lip and chin. The effects of an altered sensation after a BSSO can be found in the patient's speech, eating, drinking and social interaction (Lee et al., 2011). Patients also complain of having difficulty in daily activities like shaving, kissing, or applying lipstick. This can lead to psychological and social issues. Informing the patient about an altered sensation to the lip and chin area after a BSSO is vital as part of the informed consent process. Lee recommends that information should be provided in as many formats as possible (Lee et al., 2011). This study

discusses the importance of having a Cone-Beam Computer Tomography (CBCT) image as part of the surgeon's pre-operative assessment of the mandibular canal.

## **2.1 History of Bilateral Sagittal Split Osteotomy**

The development of the BSSO is documented in many historical texts about orthognathic surgery. BSSO of the mandible was first introduced by Schuchardt (Schuchardt, 1942). However, Obwegeser and Trauner (Trauner and Obwegeser, 1957), must be credited with the current popularity of the procedure. In 1953, Obwegeser performed the first mandibular sagittal split intra-orally on one side where he carried the medial osteotomy to the posterior border of the mandible and the vertical limb to the region of the antegonial notch. The other side was treated by Trauner, who performed the usual L-shaped osteotomy extra-orally.

Several modifications have been developed since, including those by Dal Pont (Dal Pont, 1961), Hunsuck (Hunsuck, 1968), Epker (Epker, 1977), and Wolford (Wolford and Rafferty, 1987,).

Dal Pont modified Obwegeser's method with the introduction of the retromolar osteotomy. This modification resulted in smaller displacement of the proximal segment due to muscle activity, which meant that the method could be used for anomalies besides prognathism, e.g. retrognathism and apertognathia. The retromolar osteotomy was performed at the distal level of the second molar, from the external oblique line to the inferior border of the mandible.

Hunsuck suggested that the medial osteotomy should be extended to the posterior region of the lingula, with no need for involvement of the posterior border of the ramus. According to his suggestion, lateral osteotomy, on the other hand, should be performed at the junction of the ramus and the body of the mandible.

Epker proposed an important change to the Obwegeser and Dal Pont method, minimizing complications such as excessive oedema, neurological complications related to the inferior alveolar bundle, haemorrhage and avascular necrosis of the segments. According to his suggestion, no blind posterior dissection and periosteal stripping of the masseteric-pterygoid sling was performed. He suggested gentle dissection of medial tissue from the ramus just above the lingula (for visual inspection of the inferior alveolar neurovascular bundle) and



elevation up to the antegonial incisures, without posterior extension. The osteotomy begins above the lingula, extending inferolaterally up to the inferior border of the mandible. The inferior cut, on the other hand, completely involves the basilar region, which makes the sagittal split easier.

## **2.2 Advantages of the Bilateral Sagittal Split Osteotomy**

The advantages of the BSSO procedure includes the broad bony overlap of the segments after repositioning of the jaw, minimal alterations in the position of the muscles and temporomandibular joint, and flexibility in repositioning the distal segment of the mandible.

## **2.3 Neurosensory Impairment as a complication of the Bilateral Sagittal Split Osteotomy**

The main post-operative complication of the BSSO of the mandible is NSI. Several risk factors for NSI after the BSSO have been mentioned in the literature. Yamauchi found that in patients with a Class III malocclusion with a long mandibular angle and small bone marrow space, the inferior alveolar nerve was found to be more lateral within the mandible and therefore had a higher incidence of NSI (Yamauchi et al., 2012). Other factors that increase the risk of NSI include excessive medial periosteal dissection (Westermarck et al., 1998), post-operative swelling (August et al., 1998), bleeding, patient age (Westermarck et al., 1998, August et al., 1998, Van Sickels et al., 2002), fixation methods (Pratt et al., 1996), direction and distance of mandibular movement (Westermarck et al., 1998, Van Sickels et al., 2002), degree of manipulation of the IAN and compromised splitting procedures (Ylikontiola et al., 2000, Westermarck et al., 1998, August et al., 1998).

Ylikontiola found that patients younger than 30 had fewer incidents of NSI. He also reported that patients having mandibular setback surgery had more NSI than patients having mandibular advancement surgery (Ylikontiola et al., 2000). In addition, it has been reported that mandibular movements greater than 7 mm result in a greater incidence of NSI (Ylikontiola et al., 2000, Van Sickels et al., 2002). Intra-operative nerve manipulation was also found to be directly linked to post-operative NSI (Ylikontiola et al., 2000, Fridrich et al., 1995, Westermarck et al., 1998). However, this was not observed in a study by August et al (August et al., 1998).

Takeuchi found that compression of the nerve trunk during mandibular setback surgery was associated with higher incidence of NSI (Takeuchi et al., 1994). Combining BSSO and genioplasty procedures also showed an increased incidence of NSI (Westermarck et al., 1998, Van Sickels et al., 2002). However, miniplate osteosynthesis following BSSO was found to be more stable with less inferior alveolar nerve damage when compared to inter-maxillary fixation with upper border wiring (August et al., 1998, Van Sickels et al., 2002).

## **2.4 Techniques to identify the Inferior Alveolar Nerve**

A common cause of injury to the IAN during a BSSO procedure is due to the variations in its anatomy. Identifying the exact intra-mandibular course of the IAN is thus important in minimizing injury to it. Generally, the intramandibular anatomy of the IAN starts at the position of the lingula and ends as it exits the mental foramen. The literature shows that this intra-mandibular course often varies in its path within the mandible (Carter and Keen, 1971).

Information on the buccolingual position of the canal of the IAN, especially in the region of the planned osteotomy, could help surgeons avoid injuring the nerve. Some reports have dealt with the examination of cadaver specimens to identify this relationship of the IAN (Tamas, 1987, Carter and Keen, 1971), while others employed panoramic radiography, tomography or computed tomography (CT) for this purpose (Nortje et al., 1977-78, Hallikainen et al., 1992, Aizenbud et al., 2011, Ueda et al., 2012, Yu and Wong, 2008, Tsuji et al., 2005, Yamamoto et al., 2002, Naitoh et al., 2010, Kamburoglu, 2009).

### **2.4.1 Identification of the Inferior Alveolar Nerve using anatomical specimens**

Carter and Keen dissected eight mandibles to review the intra-mandibular course of the IAN (Carter and Keen, 1971). They classified the distribution of the IAN into three types. Type I represents the IAN as a single large structure lying in a bony canal in close proximity to the roots of the molar teeth. In Type II the nerve is situated lower down in the mandible, some distance from the roots of the molars whereas in Type III the IAN gives off two large branches posteriorly while the main nerve occupies a more inferior position as it progresses towards the mental foramen.

Tamas studied the mandibles of 82 cadavers with anterior-posterior radiographs and found the following results: the distance between the mandibular canal and the lateral cortical plate of the ramus of the mandible was found to be important when considering BSSO and possible IAN impairment (Tamas, 1987). He concluded that cancellous bone less than 1 mm thick between the canal and the lateral cortical plate could be associated with a higher incidence of IAN injury.

#### **2.4.2 Identification of the Inferior Alveolar Nerve using Two-dimensional Images**

Further canal location techniques involve two-dimensional (2D) images. CJ Nortje reviewed 3612 panoramic radiographs and reported that the mandible canal is usually single and bilaterally symmetrical (Nortje et al., 1977-78). However, supplemental mandibular canals, large enough to be seen on panoramic radiographs, are occasionally present. In about 3% of cases there was duplication or division of the mandibular canal, partial or complete absence of radiographic features, and or lack of symmetry.

When employing Cross-sectional Tomography, Hallikainen found that the visibility of the mandibular canal was excellent or good in only 65.5% of cases, and invisible in 3.6% of cases (Hallikainen et al., 1992). He also noted that the distance between the canal and the buccal cortex was less in cases of prognathism than in retrognathic patients, a finding supported by others (Yamauchi et al., 2012).

#### **2.4.3 Reliability of Anatomical Specimens and Two-dimensional Images when identifying the Inferior Alveolar Nerve**

When using dry human mandibles to identify the position of the IAN, conventional radiographic techniques have severe limitations. These include shrinkage of the dry specimen resulting in possible fracture of subtle structures, magnification, distortion and questionable reproducibility of radiographic images. This type of data is thus not optimal in identifying the exact position of the nerve (Angelopoulos et al., 2008).

#### **2.4.4 Identification of the Inferior Alveolar Nerve using Cone Beam Computer Tomography**

Cone Beam Computer Tomography (CBCT) is a promising modality which reduces patient exposure compared to ordinary Computed Tomography (Ludlow et al., 2008). Three-dimensional (3D) Computed Tomography (CT) reconstruction provides quantitative anatomic data on the vital human mandible at any section without the abovementioned drawbacks (Kamburoglu et al., 2009). Studies comparing CBCT to other radiographic techniques suggest that CBCT images are superior in identifying the mandibular canal (Angelopoulos et al., 2008, Naitoh et al., 2010). When comparing CBCT to panoramic radiography the radiation dose is higher, but sensitivity in identifying the IAN during BSSO is superior to that of an Orthopantomogram (De Vos et al., 2009, Ylikontiola et al., 2002). In comparison to conventional CT, CBCT has the following advantages: the radiation exposure dose is lower, it can be employed effectively in a dental unit and the resolution of the scan is higher than in conventional CT (Naitoh et al., 2010, De Vos et al., 2009).

Ylikontiola compared three radiographic methods to locate the mandibular canal in patients requiring BSSO (Ylikontiola et al., 2002). He found that the buccolingual location of the mandibular canal was more clearly visible when analysed by conventional CT than in conventional tomography or panoramic radiography. In this study specific dimensions were also noted i.e. mean thickness of the mandibular canal to the buccal cortex behind the third molar was 2.5 mm and 3.5 mm between the first and second molar respectively.

Yamamoto evaluated the location of the mandibular canal in the ramus of the mandible before a BSSO and examined its relationship with post-operative NSI (Yamamoto et al., 2002). Twenty patients underwent CT scans before surgery. Twelve CT scans were obtained at 2 mm intervals from a base plane containing the lowest point of the mandible foramen to 22 mm below it and the distance between the mandible canal and the inner surface of the external cortical bone was measured. In all patients the mandibular canal could be assessed. He concluded that NSI was significantly more likely to be present one year after surgery when the width of the marrow space between the mandibular canal and the external cortical bone was 0.8 mm or less. NSI was found in all cases of the study in which the marrow space was absent. He found that separating the IAN from the external cortical bone without injuring

it was difficult when a marrow space was absent. This study had limitation as it did not allude to the entire course of the mandibular canal from the lingula to the mental foramen.

Nakagawa assessed the relationship of the IAN to the osteotomy site after BSSO for patients with mandibular prognathism and correlated the nerve/osteotomy relationship as a cause of NSI (Nakagawa et al., 2003). His study showed that the narrower the distance between the canal and the split surface of the mandible, the greater the severity of NSI. He strongly recommended consulting a pre-operative CT scan of the mandible to prevent NSI. He also mentioned the exposure of the IAN during the split as a major cause of trigeminal nerve hypoaesthesia.

Agbaje investigated CBCT-based predictability of the attachment of the IAN to the proximal segment of the mandible during Sagittal Split Osteotomy (SSO) (Agbaje et al., 2013). During the procedure he found that the distances from the inferior alveolar canal to the buccal cortex and lingual cortex are respectively predictive of whether the IAN will be attached or free from the proximal segment of the mandible and that the bigger the distance between the IAN and the buccal and lingual cortex, the greater the probability that the IAN will be free during the sagittal split of the mandible. He mentioned that many variables not yet studied may also be responsible for the position of the IAN during the splitting process.

Tsuji investigated the position and course of the mandibular canal using CT imaging with relevance to the Sagittal Split Ramus Osteotomy (SSRO) (Tsuji et al., 2005). He investigated the mandibles of 35 patients with skeletal Class III prognathism which required mandibular setback surgery. The following parameters were measured: total thickness of the mandible through the centre of the mandibular canal; diameter of the inner mandibular canal; narrowest portion of the bone marrow space between the outer mandibular canal and both the lateral and medial cortical bone of the ramus. The thickness of the mandible increased from the mandibular foramen to the mandibular body, the inner diameter of the mandibular canal stayed the same and on average was situated more lingually at the studied sites. The width of the buccal side bone marrow space at each site could be classified into three types: Type 1 - separate type with the bone marrow space visible; Type 2 - here the outer surface of the canal and inner surface of the buccal cortical bone are in contact, and Type 3 - a fusion type with the outer cortical plate of the canal not evident. The separate type, i.e. Type 1, was most prevalent followed by Type 2 (contact) and Type 3 (fusion type).

Yu used 3-Dimensional CT to evaluate the mandibular anatomy related to SSRO in 40 Taiwanese patients (Yu and Wong, 2008). Results regarding the position of the IAN at the second molar concluded that the mean bone thickness from mandibular canal to buccal plate was 7.2 +/- 1.47 mm and to the lower border, 7.6 +/- 1.69 mm. They also found that the mean bone thickness of the female group was less than that of the male group. Results regarding the position of the IAN at the sagittal osteotomy site concluded that the mean distance from mandibular canal to anterior margin of the ramus at the coronal section of the mandibular foramen was 12.9 +/- 2.51 mm, with a maximum of 19.6 mm and a minimum of 9.2 mm. They also found that the dimension of the female mandibles in the study group was smaller than that of their male counterparts.

Wittwer evaluated the risk of injury to the IAN with SSO using CT data from 102 mandibular rami (Wittwer et al., 2012). He mentions the use of CBCT for surgical guidance and its importance during pre-operative planning. He studied the distance between the mandible canal and the inner surface of the cortical bone at three different sites. These sites included a coronal position 3 mm anterior of the mandibular foramen, at the transition of the ramus to the mandibular body and in the middle of the distance of the last mentioned to distal of tooth seven. He also assessed the canal in a horizontal position. He concluded that only 40% of SSO sites showed that the IAN was not in proximity to the inner buccal cortex of the mandible. This indicates that the possibility of nerve injury based only on nerve proximity to the buccal plate may in reality be about 60% of SSO's. It is therefore their opinion that patients should have an pre-operative assessment of the IAN based on a CT scan before undergoing a SSO. No clinical data to support their findings are found in the study.

Aizenbud found no significant NSI after BSSO (Aizenbud et al., 2011). He concluded that his improved results regarding NSI might be related to the use of CBCT technology as part of his pre-surgical planning.

It is important to consider each patient's individual risk of NSI, based on the mandible morphology, as determined by pre-operative images. It is the opinion of Yamauchi et al. that pre-operative evaluation of medical images is important for assessing the risk of complications and improving the doctor-patient relationship (Yamauchi et al., 2012).

# CHAPTER 3

## RESEARCH DESIGN AND METHODOLOGY

### AIM AND OBJECTIVES

#### **Aim**

The aim of the study was to investigate a correlation between the intra-operative position of the Inferior Alveolar Nerve (IAN) and the nerve position as noted on a pre-operative Cone Beam Computer Tomography (CBCT) scan in patients requiring Bilateral Sagittal Split Osteotomy (BSSO) of the mandible.

#### **Objectives**

The objectives of the prospective study were:

1. Assessing the three-dimensional position of the mandibular canal at predetermined areas with the use of pre-operative CBCT.
2. The clinical assessment of the IAN intra-operatively during the BSSO of the mandible

# METHODOLOGY

## Study design

This study was a prospective case series of patients selected for BSSO procedures at the department of Maxillo-Facial and Oral Surgery, Tygerberg Oral Health Centre, University of the Western Cape.

## Study population

The study population comprised of patients undergoing a BSSO between 2013 and 2014 at the Department of Maxillo-Facial and Oral Surgery, Tygerberg Oral Health Centre, University of the Western Cape.

## Patients and methods

The sample size was 10 patients who met the inclusion criteria.

Inclusion criteria:

- Symmetrical jaw growth
- Normal IAN function
- Patients requiring a BSSO procedure to correct retrognathia and prognathia
- Prior removal of third molars (at least > 6 months)
- Dentate patients

Exclusion criteria:

- Patients with traumatic injury to the mandible
- Syndromic conditions
- Congenital anomalies
- Asymmetry of the mandible
- Previous surgery to the mandible
- Pathology to the mandible
- Edentulous patients
- Abnormal IAN function





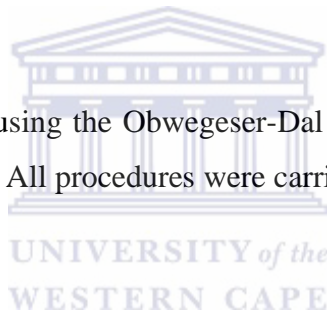
## **Anesthetic Technique**

Surgery was performed under standardised general anaesthesia protocol. An intravenous catheter was inserted. At induction patients received Propofol 2 mg/kg and Fentanyl 3-5 mcg/kg. Rocuronium bromide (Esmeron<sup>®</sup>) 0.6 mg/kg was administered as a non-depolarising neuromuscular blocker. Laryngoscopy and nasotracheal intubation was performed with placement of a ribbon gauze throat pack. During the surgical procedure the patient was kept anaesthetized with Sevoflurane or Isoflurane. At the conclusion of surgery the action of the muscle relaxant was reversed with Neostigmine 0.05 - 0.07 mg/kg and Glycopyrolate 0.2 mg.

The IV antibiotics, Augmentin<sup>®</sup> 1.2g, and Dexamethasone 4mg were administered intra-operatively. This was discontinued 48 hours post-surgery.

## **Surgical Technique**

All the BSSO's were performed using the Obwegeser-Dal Pont technique with modification described by Hunsuck and Epker. All procedures were carried out under general anesthesia as previously described.



A rubber mouth prop ensured mouth opening. A local anesthetic containing a vasoconstrictor was used to infiltrate all areas of dissection. An incision was made through the mucosa, muscle and periosteum from external oblique ridge inferiorly towards the first molar. A minimum of 5 mm of non-keratinized mucosa was left buccally to ease suturing at the end of surgery. A bipolar diathermy was used to control bleeding.

Medial subperiosteal ramal dissection was carried out posteriorly to help identify the lingula. Attachment of the masseter muscle was maintained as far as possible without sacrificing adequate exposure.

Once the buccal and lingual sides of the anterior ascending ramus were exposed, a swallow-tail Langenbeck retractor was placed at the coronoid aspect of the ramus to assist in stripping the lower fibers of the temporalis muscle attachment. Medial subperiosteal dissection to expose the lingula and to identify the entry of the inferior alveolar nerve was done with great care. The medial ramus osteotomy was marked using a 701 fissure bur aiming just above the

lingula and keeping parallel to the occlusal plane. The osteotomy was carried through the lingual cortex into the medullary bone of the ramus and ended just posterior and above the lingula.

The vertical section of the osteotomy commenced using a small round bur from the superior medial osteotomy inferiorly and ended mesial to the second molar. Pilot holes were made just through the cortex and later connected with the use of a piezoelectric device. The mouth prop was removed and a channel retractor placed around the inferior border of the mandible.

Using a small round bur, small pilot holes were made through the cortex of the buccal bone to facilitate the buccal and inferior border osteotomy of the body of the mandible. Later these holes were connected with the use of piezoelectric device. All osteotomy sites were connected with the piezoelectric device. A mirror image osteotomy was performed on the opposite mandible.

The splitting of the mandible was facilitated by small, sharp chisels which were driven directly into the inner aspect of the buccal cortex and then eased down to closely follow the buccal cortical wall while remaining lateral to the neurovascular bundle. The IAN was observed in its intraosseous bed and its position compared to the pre-operative CBCT image. It was identified as being either attached to the proximal or to the distal part of the mandible. If it was attached to the proximal segment, it was carefully removed. If the IAN was still encased within the mandibular canal, the piezoelectric device was used to free it. Information regarding the intra-operative position of the IAN noted in the patient's surgical records. This information was divided into the following categories:

1. The IAN present in the distal segment of the mandible
2. The IAN lying free between the distal and proximal segments of the mandible
3. The IAN present in the proximal segment of the mandible and needs to be released

To facilitate the movement of the mandible it was sometimes necessary to strip the pterygomasseteric sling, medial pterygoid muscle and stylomandibular ligament. While protecting the IAN, all sharp bony segments were smoothed with a large pear-shaped bur.

Using a custom positional acrylic splint, the patient was placed in maxillomandibular fixation (MMF) with the use of 0.356mm ligature wire securing the mandible in its occlusal relationship to the maxilla. Fixation was obtained via a buccally placed mini-plate and four unicortical screws. MMF was released after satisfactory fixation was achieved.

Low-pressure vacuum drains were used to help with post-operative edema where needed. Wounds were closed with resorbable sutures.

For mandibular setback, it was usually necessary to remove bone from the proximal segment. The amount of bone removed corresponded to the amount of mandibular setback required as determined by the surgeon.

### **Presurgical Imaging and Planning**

Orthopantomogram, lateral cephalogram and CBCT formed part of the presurgical imaging and planning. CBCT of the mandible was performed using a NewTom VGi machine in parallel to the Frankfort horizontal plane at 0.5 mm intervals with a slice thickness of 0.3 mm.

Panoramic and cross-sectional reconstructions were created from the CBCT scan using NNT Viewer imaging software Version 2.21 in accordance with the manufacturer's instructions (Figure 1 & 2). With the use of the software the IAN was identified (Figure 3, 4 & 5). Cross-sectional images of the mandible starting from the lingula and ending distal to the second molar were reconstructed and assessed as follows (Figure 6):

- The mean width of the marrow space between the inferior alveolar canal and the buccal, lingual, superior and inferior cortical bone was calculated at three sites:
  - a. Site 1: At the lingula (X) (Figure 7 & 8)
  - b. Site 2: Midpoint between Site 1 and Site 3 (Y) (Figure 9)
  - c. Site 3: Distal to second molar of the mandible (Figure 10)

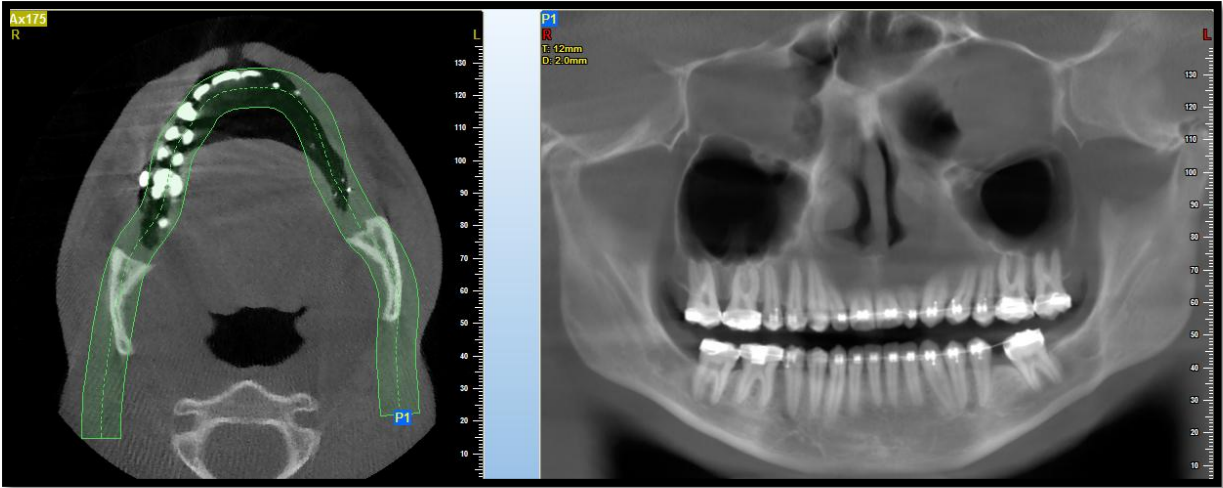


Figure 1: Orthopantomogram 12 mm in thickness

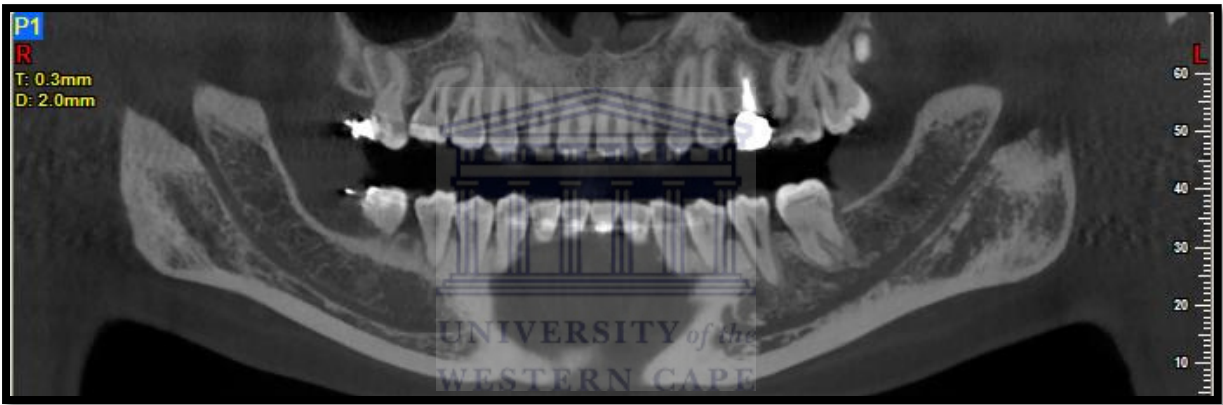


Figure 2: Orthopantomogram 0.3 mm thick for identification of inferior alveolar canal

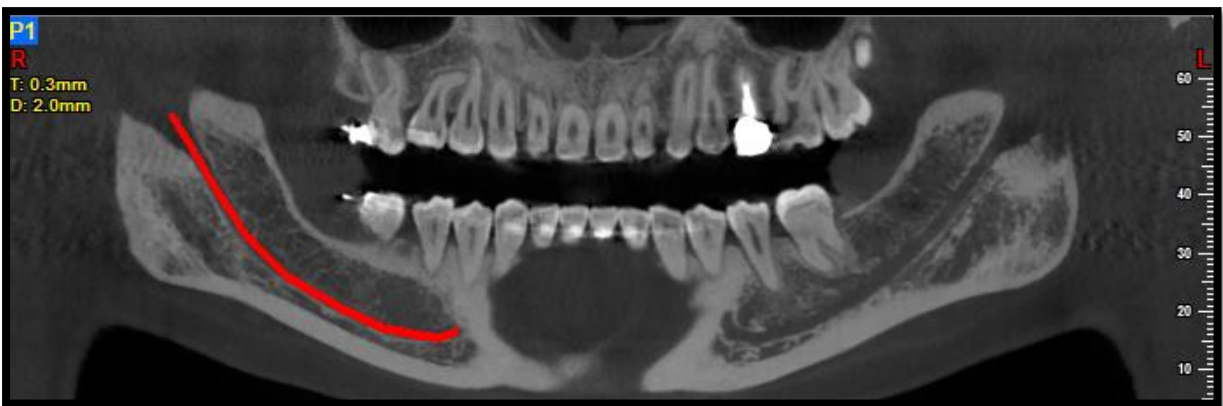

Figure 3: Identification of inferior alveolar nerve (in red)

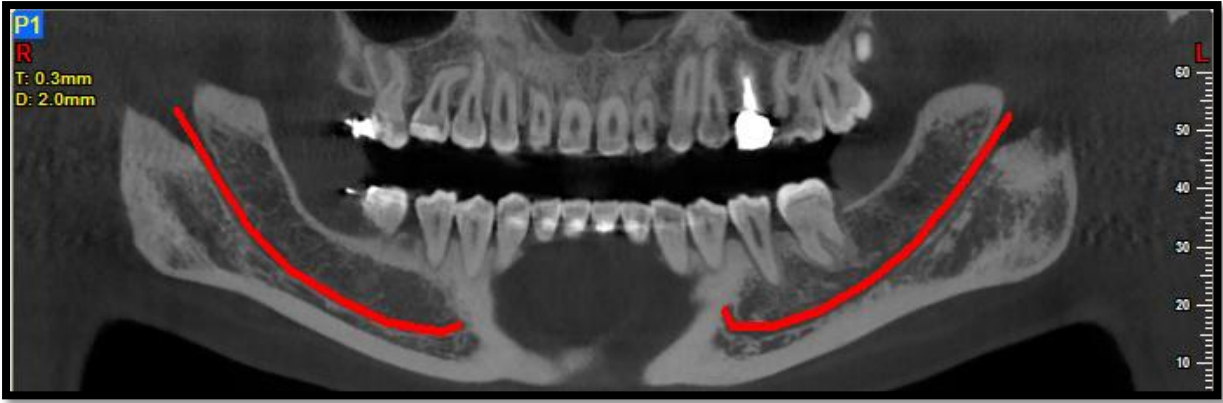


Figure 4: Identification of inferior alveolar nerve left and right side of mandible (red line)

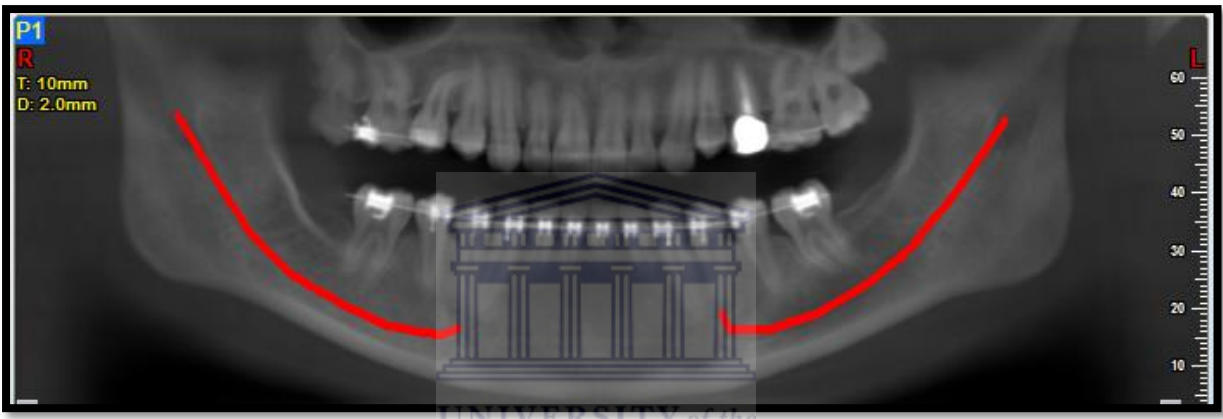


Figure 5: Orthopantomogram 10 mm thick with identification of inferior alveolar nerve

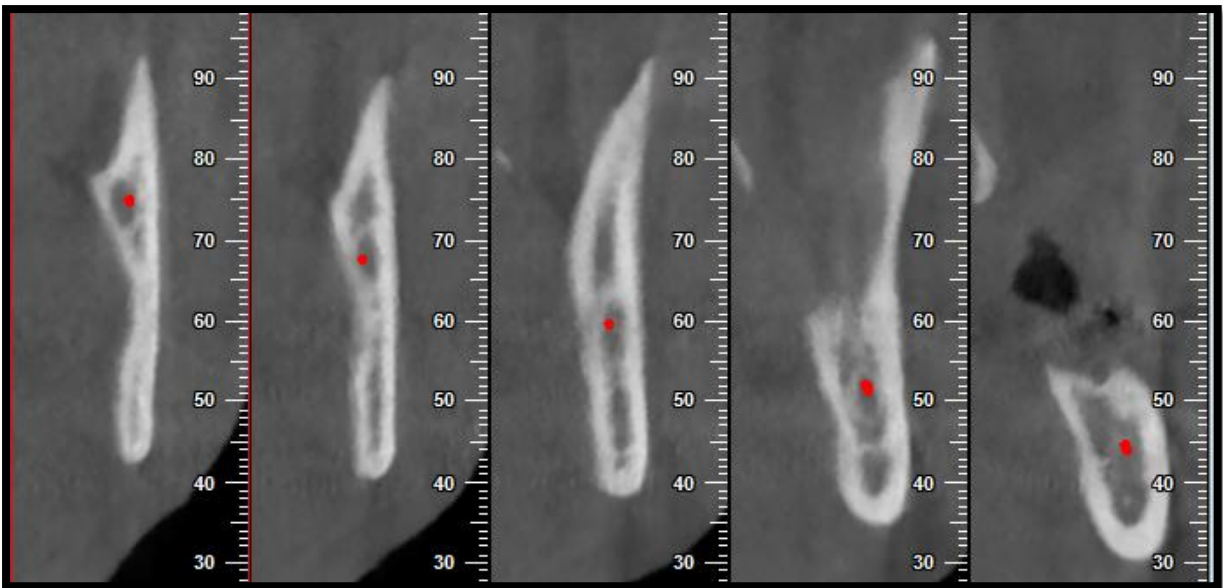


Figure 6: Cross sectional cuts from Lingula to distal aspect of second molar. Inferior alveolar nerve represented by red dot

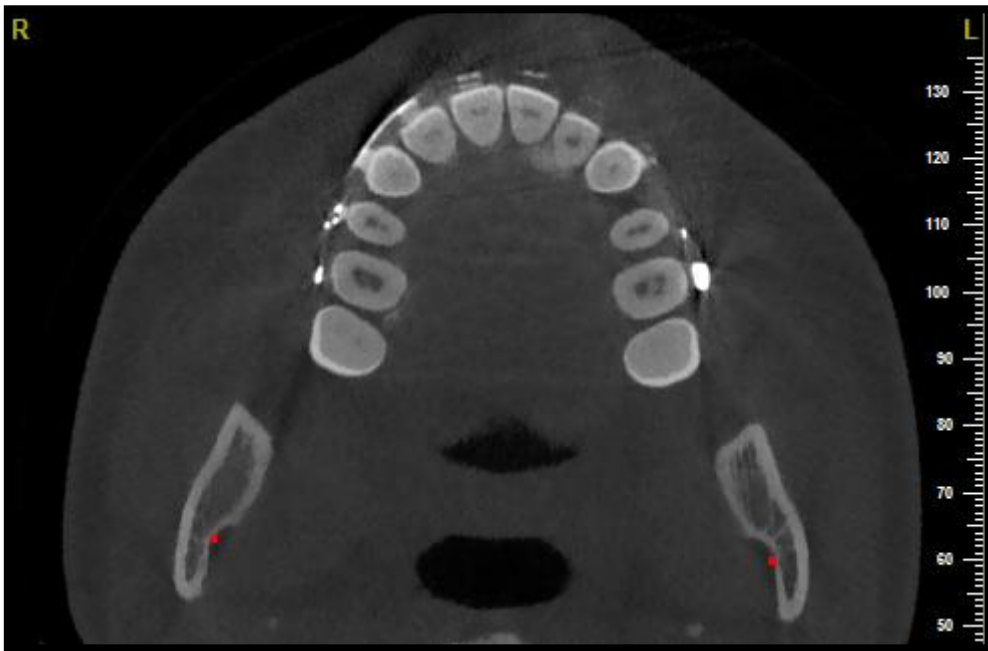


Figure 7: Inferior alveolar nerve as it enters the inferior alveolar canal

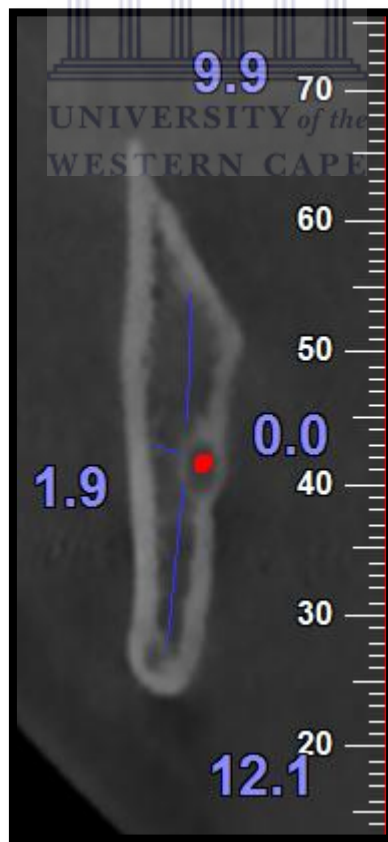


Figure 8: Cross section (0.5 mm slice) at the level of the Lingula (X) with measured values of the medullary bone present at point X

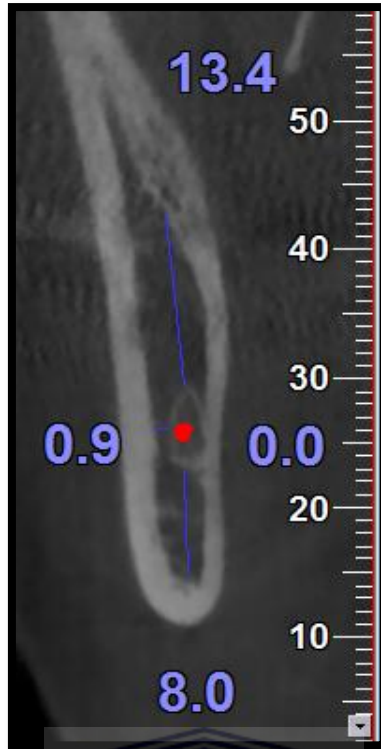


Figure 9: Cross section (0.5 mm slice) midpoint (Y) between the lingula (X) and distal part of second molar (Z)

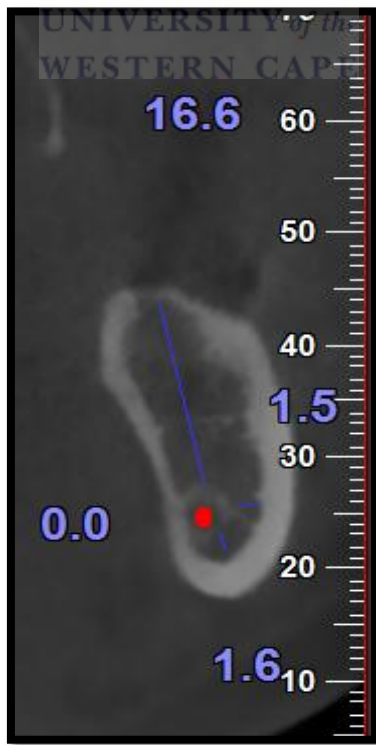

Figure 10: Cross section (0.5 mm slice) distal part of second molar (Z). Note how close the inferior canal is to the lingual and lower cortex.

### **Postoperative management**

All patients were admitted to Surgical Intensive Care Unit (ICU) postoperatively and transferred to the general Maxillo-Facial and Oral Surgery ward on day one. All patients were discharged three days post-operatively.

Patients were discharged with the following:

- 1 g Paracetamol orally 6-hourly for five days
- 400 mg Ibuprofen orally 6-hourly for five days
- 0.2% Chlorhexidine gluconate mouthrinse - 15 ml rinse after meals
- A departmental post orthognathic surgery patient information letter

### **Criteria that were evaluated**

1. Cone-beam Computer Tomography measuring the width of the marrow space between the mandibular canal and the outer, inner, upper and lower cortical bone at predetermined points (X, Y and Z).
2. Information regarding the intra-operative position of the IAN was obtained during surgery and divided in the following categories:
  - IAN present in the distal segment of the mandible
  - IAN lying free between the distal and proximal segments of the mandible
  - IAN present in the proximal segment of the mandible and needs to be released

### **Data Management and Statistical Analysis**

All data were collected and transferred from the data collection sheet (Appendix I) to a spreadsheet (Microsoft Office Excel<sup>®</sup> 2010) and analysed statistically using a standard statistics programme (Epi-Info Version 7). The statistical testing of differences among the group was done using the Student's t-test with significance judged as  $P < 0.05$ .



## **Ethical Statement**

The research protocol was presented to the Research Committee of the Faculty of Dentistry, UWC, and approved as a research project. Patient participation in the project was voluntary. Each patient had the right to withdraw from the study at any stage and the latter did not prejudice the patient in any way with regard to further treatment at the facility. Every patient was informed about the project and handed a formal information leaflet in English. All patients were asked to give informed consent or refusal for the research project through a formal written consent procedure. Patient confidentiality was protected at all times. All information was stored in password-protected computers and printed information was stored in a locked office. All personal identifiers were changed when the data were published. Photographs were used with informed consent and eyes were blocked out.



# CHAPTER 4

## RESULTS

### 4.1 Demographic Information and Procedure Type

The analysis included 20 operation sites (OPS) from 10 subjects (6 females, 4 males). Mandibular advancement was performed on 2 subjects and mandibular setback on 8 subjects. The mean age of the sample was 19.7 years (SD=1.95). Table 1 represents the demographic information and procedure type.

**Table 1: Demographic information and procedure type**

Pt	Age	Sex	Procedure Type
1	20	M	Mandibular Setback
2	20	F	Mandibular Advancement
3	20	M	Mandibular Setback
4	17	F	Mandibular Setback
5	23	F	Mandibular Setback
6	22	F	Mandibular Setback
7	17	F	Mandibular Setback
8	18	F	Mandibular Setback
9	20	M	Mandibular Setback
10	20	M	Mandibular Advancement

### 4.2 Intra-operative Identification of the Inferior Alveolar Nerve

In one third of OPS (7 sites) the IAN was lying free. In 15% of OPS (3 sites) the IAN was lying within the distal segment of the mandible and no manipulation of the IAN was required. In 50% of OPS (10 sites) the IAN was found attached to the proximal segment of the mandible. In all of these sites where the IAN was attached to the proximal segment, the IAN had to be released with the help of a piezoelectric device. No nerve transection was observed in any patient. Variables were measured at the lingula (X), distal segment of second molar (Z) and a point between X and Z (Y).

### 4.3 Measured Distance between the Inferior Canal and Mandibular Cortices

4.3.1: The distance between the IAC and the Buccal Cortical Border (BCB) for 10 subjects at left and right sides of the mandible are represented in Table 2

**Table 2: Distance between IAC and BCB**

No	Distance between IAC and BCB					
	X	Y	Z	X	Y	Z
Pt	Left			Right		
1	1.1	0.35	0.4	0.0	0.6	1.5
2	1.4	3.2	4.3	0.6	1.9	3.9
3	0.0	0.0	2.8	0.3	1.15	3.0
4	0.3	0.8	1.5	0.6	0.5	0.9
5	0.0	0.4	1.2	1.6	2.2	4.5
6	0.9	3.5	3.5	0.0	2.6	2.6
7	0.6	2.7	1.8	0.0	1.9	2.7
8	0.3	0.6	1.2	0.9	0.0	0.0
9	1.4	0.6	3.0	0.0	1.25	4.0
10	0.8	0.9	3.0	0.8	1.5	5.1

4.3.2: The distance between the IAC and the Lingual cortical border (LCB) for 10 subjects at left and right sides of the mandible are represented in Table 3

**Table 3: Distance between IAC and LCB**

No	Distance between IAC and LCB					
	X	Y	Z	X	Y	Z
Pt	Left			Right		
1	0.3	0.6	2.3	0.0	0.45	0.0
2	0.0	0.0	0.0	0.0	0.0	0.0
3	0.0	0.0	0.0	0.0	1.2	2.7
4	0.0	0.0	0.3	0.3	0.35	0.8
5	0.0	0.0	0.0	0.0	0.0	0.0
6	0.0	0.0	0.3	0.0	0.4	0.0
7	0.0	0.0	0.0	0.3	1.5	0.0
8	0.0	0.3	0.0	0.3	1.5	0.0
9	0.0	0.85	0.8	0.0	1.5	0.0
10	0.3	0.6	0.0	0.2	0.5	0.0

4.3.3: The distance between the IAC and the inferior cortical border (ICB) for 10 subjects at left and right sides of the mandible are represented in Table 4

**Table 4: Distance between IAC and ICB**

	Distance between IAC and ICB					
No	X	Y	Z	X	Y	Z
Pt	Left			Right		
1	25.5	12.00	3.9	24.8	6.75	0.0
2	11.4	5.25	4.0	13.7	7.55	3.9
3	18.9	9.00	5.8	19.8	8.45	4.3
4	17.1	8.75	3.8	17.4	8.40	6.3
5	11.1	4.65	1.2	10.6	5.00	1.7
6	5.1	3.20	2.0	6.9	2.70	1.7
7	7.5	2.80	1.5	9.0	3.30	1.2
8	7.2	1.50	0.0	11.8	2.10	0.0
9	19.9	8.15	2.8	10.7	4.90	2.6
10	17.8	6.10	2.9	16.7	6.40	2.1

4.3.4: The distance between the IAC and the superior cortical border (SCB) for 10 subjects at left and right sides of the mandible are represented in Table 5

**Table 5: Distance between IAC and SCB**

	Distance between IAC and SCB					
No	X	Y	Z	X	Y	Z
Pt	Left			Right		
1	1.3	6.50	8.1	4.8	4.50	6.6
2	11.7	13.40	12.0	10.3	13.55	12.1
3	10.2	9.90	12.2	8.7	8.55	9.3
4	6.3	11.00	10.4	8.7	12.45	9.7
5	13.0	15.85	12.8	11.7	12.60	12.5
6	12.0	14.95	16.8	11.8	12.00	12.9
7	14.1	9.30	10.9	15.0	9.40	8.4
8	9.6	8.75	8.0	8.2	8.90	9.0
9	3.6	3.85	7.7	9.5	8.65	9.8
10	12.3	16.40	11.9	13.7	14.20	14.0

#### 4.4 Mean Distance between the Inferior Alveolar Canal and the Mandibular Cortices

The mean distances between the IAC to the BCB of the mandible at the X, Y and Z for 20 OPC's are represented in Table 6.

**Table 6: Mean Distance between the IAC and the Outer Cortex at Point X, Y and Z**

	Mean Distance (mm)
X	0.58 (SD=0.53)
Y	1.33 (SD=1.06)
Z	2.55 (SD=1.44)

In half of the OPS's the nerve was manipulated. Measured variables, grouped by manipulation of the nerve and the mean distance between the LCB, BCB, SCB and ICB at X, Y, Z and procedure type are discussed below.

##### 4.4.1 Mean distance between the LCB and the IAC

There was no significant difference in the mean distance from the IAC to the LCB of the mandible in patients who had no manipulation of the IAN compared to those where the IAN was manipulated at X, Y and Z ( $p > 0.05$ ).

##### 4.4.2 Mean distance between the ICB and the IAC

The distance between the IAC and the ICB of the mandible was less in the OPC group who had manipulation of the IAN at points X, Y, Z. This difference was statistically significant at points X and Y ( $p < 0.05$ ), but not at point Z.

##### 4.4.3 Mean distance between the SCB and IAC

There was no significant difference in the distance from the IAC to the SCB of the mandible in patients who had no manipulation of the IAN compared to those where the IAN was manipulated at X, Y and Z ( $p > 0.05$ ).

##### 4.4.4 Mean distance between the BCB and IAC

There was no significant difference in the distance from the IAC to the BCB of the mandible in patients who had no manipulation of the IAN compared to those where the IAN was manipulated at X, Y and Z ( $p > 0.05$ ).

#### 4.4.5 Procedure type compared with nerve manipulation

There was no relationship found between procedure type (mandibular setback and advancement) and nerve manipulation ( $p > 0.05$ ).

#### 4.4.6 Mean distance between the IAC and BCB compared to procedure type

The mean distance between the IAC and the BCB at point Z was less in patients who underwent mandibular setback surgery than in those who had mandibular advancement surgery and the difference was statistically significant ( $p < 0.05$ ). At point X and Y there was no significant statistical difference found.



## CHAPTER 5

### DISCUSSION

Post-operative hypoesthesia is a known complication after orthognathic surgery. It can be caused by direct or indirect injury to the inferior alveolar nerve (IAN). Post-operative IAN nerve injury is reportedly the highest in patients undergoing a Bilateral Sagittal Split Osteotomy (BSSO) (Coghlan and Irvine, 1986), the most common procedure for managing mandibular asymmetries, mandibular retrognathism and mandibular prognathism (Westermarck et al, 1998).

In BSSO, the osteotomy is performed in close proximity to the IAN. Consequently the main post-operative complication of a BSSO is neurosensory impairment (NSI) (Yamauchi et al., 2012). Direct damage to the IAN during an osteotomy can be caused by surgical instruments including needles, saws, retractors, burs, chisels or miniplate osteosynthesis. Indirect injury to the IAN may result from post-operative oedema or haematoma (Panula et al., 2001).

Direct damage to the IAN trunk during an osteotomy and nerve release can be reduced with the use of a piezoelectric device. In the study, the piezoelectric device used was a Surgybone<sup>®</sup> (Figure 11) by Silfradent Srl.

The Surgybone<sup>®</sup> is an electromedical instrument that performs operations by means of ultrasound microvibrations produced by a piezoelectric transducer. Micrometric cutting allows for the use of osteoplastic and osteotomy techniques providing maximum visibility, precision and safety together with minimum tissue damage. The limited vibration amplitude makes the cutting process safe: even in the event of an operator mistake on nerves and soft tissues, there would be no immediate damage, unless you performed the procedure with an incorrect, continuative action. In all the cases where bone had to be removed to free the nerve from the proximal segment, the piezoelectric device was used in the current study with no clinical injury to the nerve. The nerve was clinically evaluated using 2.5X surgical loops.

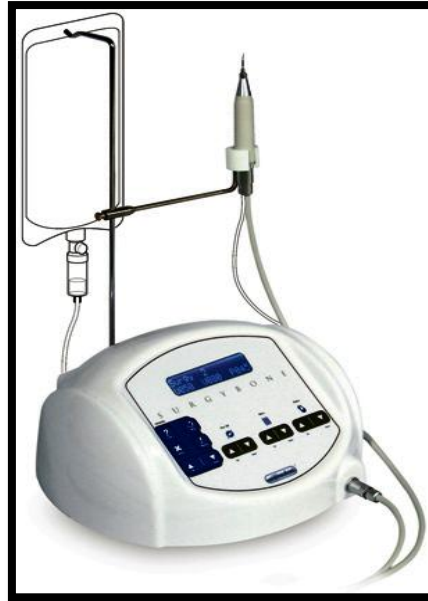

Figure 11: Surgybone<sup>®</sup>

Knowledge of the location of the IAN when contemplating a BSSO procedure is important because it can improve surgical planning and reduce complications. Having a Cone Beam Computer Tomography (CBCT) scan as part of the surgeon's pre-operative assessment of the mandibular canal is deemed important (Lee et al., 2011). Information on the buccolingual, superior and inferior position of the canal, especially in the region of the planned osteotomy, could help surgeons avoid injury to the IAN (Nakagawa et al., 2003).(Fig 12).

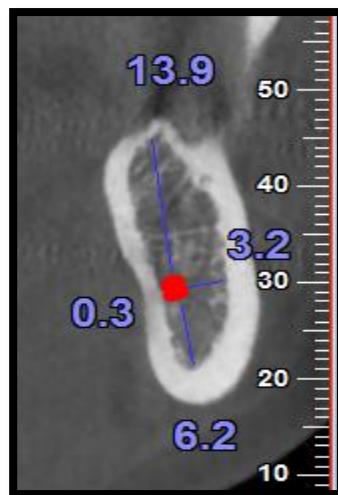


Figure 12: Measured distances from the inferior alveolar canal to mandibular cortex



Knowledge regarding the amount of medullary bone available between the Inferior alveolar canal (IAC) and the planned osteotomy is also deemed important (Nakagawa et al., 2003). In their study, it appeared that the presence of reduced medullary bone (Figure 13) between the IAC and the cortex of the mandible is associated with a higher risk for IAN manipulation.

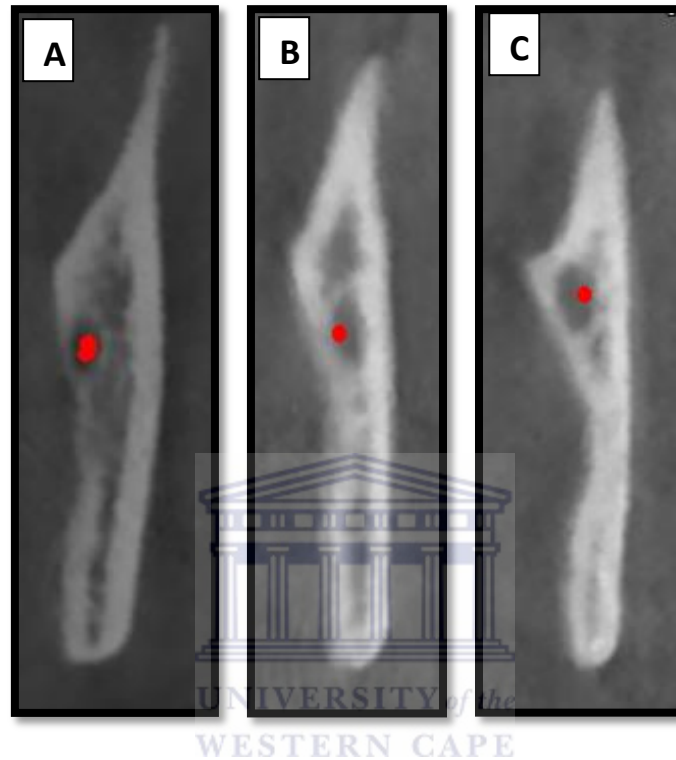


Figure 13: A: Inferior alveolar canal in contact with buccal and lingual cortex, B: Inferior alveolar canal in contact with lingual cortex with minimal medullary bone present, C: Inferior alveolar canal present with no medullary bone present

In the current study, the mean distance between the IAC and the BCB at point Z was statistically significantly less in patients who underwent mandibular setback surgery than in those who had mandibular advancement surgery, a finding supported by others (Hallikainen et al., 1992, Yamauchi et al., 2012). At point X and Y no statistically significant difference was found.

In addition, the IAN was lying free in one third of operational sites (OPS) (7 sites). In 15% of OPS (3 sites) the IAN was lying within the distal segment of the mandible and no manipulation of the IAN was required. In 50% of OPS (10 sites) the IAN was found attached

to the proximal segment of the mandible. In all of these sites the IAN had to be released with the help of a piezo-electric device. No nerve transection was observed in any patient.

Yamauchi found the IAN to be more lateral within the mandible of patients requiring mandibular setback surgery and reported a higher incidence of NSI in these patients (Yamauchi et al., 2012). In this study, no association was found between procedure type (mandibular setback or advancement) and nerve manipulation.

Ylikontiola analysed the buccolingual location of the mandibular canal by conventional CT and found that the mean thickness of the mandibular canal to the buccal cortex was 2.5 mm and 3.5 mm between the first and second molar respectively (Ylikontiola et al., 2002). The present study found similar results with the use of CBCT scan. The mean distance between the IAC and the outer cortex distal to second molar was 2.55 mm (SD=1.44).

The distance between the IAC and the ICB of the mandible was less in the OPC group who had manipulation of the IAN and points X, Y and Z. This difference was statistically significant at points X and Y ( $p < 0.05$ ), but not at point Z. There was no significant difference in the distance from the IAC to the LCB of the mandible in patients who had no manipulation of the IAN compared to those where the IAN was manipulated at X, Y and Z ( $p > 0.05$ ). Likewise, there was no significant difference in the distance from the IAC to the ICB of the mandible in patients who had no manipulation of the IAN compared to those who the IAN was manipulated at X, Y and Z ( $p > 0.05$ ). This was in contrast with the findings reported by Agbaje et al. in 2013. Agbaje investigated CBCT-based predictability of the attachment of the IAN to the proximal segment of the mandible during sagittal split osteotomy (Agbaje et al., 2013). He found that the distances from the inferior alveolar canal to the buccal cortex and lingual cortex respectively are predictive of whether the IAN will be attached or free from the proximal segment of the mandible during sagittal split osteotomy of the mandible. Furthermore, that the bigger the distance between the IAN and the buccal and lingual cortex, the greater the probability that the IAN will be free during the sagittal split of the mandible. Agbaje concluded that it is difficult to obtain an exact distance to use as a standard for predicting whether the nerve will be free or attached to the proximal or distal segment of the mandible.

The results of the current study demonstrated that the mean distances from the IAC to the lower border of the mandible at point X and Y are important predictors of whether the IAN will be attached to the proximal segment of the mandible, thus needing manipulation and therefore increasing the probability of NSI. Due to the small sample size these results are mainly informative. Larger studies would be needed to conclusively verify the relationship between the location of the IAC and predicting the position of the IAN with the help of pre-operative CBCT.

## **CONCLUSION AND RECOMMENDATION**

It is important to consider each patient's risk of NSI according to their mandible morphology. This can be assessed from pre-operative CBCT imaging. From this study it can be concluded that a CBCT scan is a useful and reliable modality in the pre-operative evaluation of patients undergoing BSSO especially with regard to the assessment and mapping of the mandibular canal. The CBCT is therefore a valuable tool in the armamentarium of the surgeon as it is helpful during the informed consent process as well as intra-operatively, where it can assist in minimising nerve damage during the BSSO procedure.

## REFERENCES

- AIZENBUD, D., CICEU, H., HAZAN-MOLINA, I., ABU-EL-NAAJ., E. 2011. Relationship between inferior nerve imaging and neurosensory impairment following bilateral sagittal split osteotomy in skeletal class III cases with mandibular prognathism. *Int J Oral Maxillofac Surg*, 41 (4): 461 – 468.
- AGBAJE, J., SUN, Y., DE MUNTER, S., SCHEPERS, S., VRIELINCK, L., LAMBRICHTS, I., POLITIS, C. 2013. CBCT-based predictability of attachment of the neurovascular bundle to the proximal segment of the mandible during sagittal split osteotomy. *Int J Oral Maxillofac Surg*, 42: 308 - 315.
- ANGELOPOULOS, C., THOMAS, S., HECHLER, S., PARISSIS, N., HLAVACEK, M. 2008. Comparison between digital panoramic radiography and cone-beam computed tomography for the identification of the mandibular canal as part of presurgical dental implant assessment. *J Oral Maxillofac Surg*, 66: 2130 - 2135.
- AUGUST, M., MARCHENA, J., DONADY, J., KABAN, L. 1998. Neurosensory deficit and functional impairment after sagittal ramus osteotomy: A long-term follow-up study. *J Oral Maxillofac Surg*, 56: 1231 - 1235.
- CARTER, R., KEEN, E. 1971. The intramandibular course of the inferior alveolar nerve. *J Anat*, 108 (3), 433 - 440.
- COGHLAN, K.M., IRVINE, G.H. 1986. Neurological damage after sagittal split osteotomy. *Int J Oral Maxillofac Surg*, 15: 369.
- DE VOS, W., CASSELMAN, J., SWENNEN, G. 2009. Cone-beam computerized tomography (CBCT) imaging of the oral and maxillofacial region: A systematic review of the literature. *Int J Oral Maxillofac Surg*, 38: 609 - 625.
- DAL PONT, G. 1961. Retromolar osteotomy for correction of prognathism. *J Oral Surg*, 19: 42 - 47.
- EPKER, B. 1977. Modifications in the sagittal split osteotomy of the mandible. *J Oral Surg*, 35: 157 - 159.
- FRIDRICH, K., HOLTON, T., PANSEGRAU, K., BUCKLEY, M. 1995. Neurosensory recovery following the mandibular bilateral sagittal split osteotomy. *J Oral Maxillofac Surg*, 53: 1300 - 1306.
- HALLIKAINEN, D., IIZUKA, T., LINDQVIST, C. 1992. Cross-sectional tomography in evaluation of patients undergoing sagittal split osteotomy. *J Oral Maxillofac Surg*, 50: 1269 - 1273.
- HUNSUCK, E. 1968. A modified intraoral sagittal splitting technique for correction of mandibular prognathism. *J Oral Surg*, 26: 249 - 252.

KAMBUROGLU, K., KILIC, C., OZEN, T., YUKSEL, S. 2009. Measurements of mandibular canal region obtained by cone-beam computed tomography: a cadaveric study. *Oral Surg Oral Med Oral Pathol Oral Radiol Endod*, 107: e34 - e42.

LEE, E., RYAN, F., SHUTE, J., CUNNINGHAM, S. 2011. The impact of altered sensation affecting the lower lip after orthognathic treatment. *J Oral Maxillofac Surg*, 69: e431 - e445.

LUDLOW, J., IVANOVIC, M. 2008. Comparative dosimetry of dental CBCT devices and 64-slice CT for oral and maxillofacial radiology. *Oral Surg Oral Med Oral Pathol Oral Radiol Endod*. 106: 106 - 114.

NAITOH, M., NAKAHARA, K., SUENAGA, Y., GOTOH, K., KONDO, S., ARIJI, E. 2010. Comparison between cone-beam and multislice computed tomography depicting mandibular neurovascular canal structures. *Oral Surg Oral Med Oral Pathol Oral Radiol Endod*, 109: e25 - e31.

NAKAGAWA, K., UEKI, K., TAKATSUKA, S., YAMAMOTO, E. 2003. Trigeminal nerve hypesthesia after sagittal split osteotomy in setback cases: Correlation of postoperative computed tomography and long-term trigeminal somatosensory evoked potentials. *J Oral Maxillofac Surg*, 61: 898 - 903.

NORTJE, C., FARMAN, A., GROTEPASS, F. 1977-78. Variations in the normal anatomy of the inferior dental (mandibular) canal: A retrospective study of panoramic radiographs from 3612 routine dental patients. *British J Oral Surg*, 15: 55 - 63.

PANULA, K., FINNE, K., OIKARINEN, K. 2001. Incidence of complications and problems related to orthognathic surgery: A review of 655 patients. *J Oral Maxillofac Surg*, 59: 1128 - 1136.

PRATT, C., TIPPET, H., BARNARD, J., BIRNIE, D. 1996. Labial sensory function following sagittal split osteotomy. *British J Oral and Maxillofac Surg*, 34: 75 - 81.

SCHUCHARDT, G. 1942. Ein Beitrag zur chirurgischen Kieferorthopadie unter Berucksichtigung ihrer fur die Behandlung angeborener und erworbener Kiefer deformitaten bie Soldaten. *Dtsch Zahn Mund Kieferheilkd*, 73 - 89.

TAKEUCHI, T., FURUSAWA, K., HIROSE, I. 1994. Mechanism of transient mental nerve paraesthesia in sagittal split mandibular ramus osteotomy. *British J Oral and Maxillofac Surg*, 32: 105 - 108.

TAMAS, F. 1987. Position of the mandibular canal. *Int J Oral Maxillofac Surg*, 16: 65 - 69.

TRAUNER, R., OBWEGESER, H. 1957. The surgical correction of mandibular prognathism and retrognathia with consideration of genioplasty. Part I. Surgical procedures to correct mandibular prognathism and reshaping of the chin. *Oral Surg Oral Med Oral Pathol*. 10 (7), 677 - 689.

TSUJI, Y., MUTO, T., KAWAKAMI, J., TAKEDA, S. 2005. Computed tomographic analysis of the position and course of the mandibular canal: relevance to the sagittal split ramus osteotomy. *Int J Oral Maxillofac Surg*, 34: 243 - 246.

- UEDA, M., NAKAMORI, K., SHIRATORI, K., IGARASHI, T., SASAKI, T., ANBO, N., KANEKO, T., SUZUKI, N., DEHARI, H., SONODA, T., HIRATSUKA, H. 2012. Clinical significance of computed tomographic assessment and anatomic features of the inferior alveolar canal as risk factors for injury of the inferior alveolar nerve at third molar surgery. *J Oral Maxillofac Surg*, 70: 514 - 520.
- VAN SICKELS, J., HATCH, J., DOLCE, C., BAYS, R., RUGH, J. 2002. Effects of age, amount of advancement, and genioplasty on neurosensory disturbance after a bilateral sagittal split osteotomy. *J Oral Maxillofac Surg*, 60: 1012 - 1017.
- WESTERMARK, A., BYSTEDT, H., VON KONOW, L. 1998. Inferior alveolar nerve function after mandibular osteotomies. *British J Oral and Maxillofac Surg*, 36: 425 - 428.
- WITTWER, G., ADEYEMO, W., BEINEMANN, J., JUERGENS, P. 2012. Evaluation of risk of injury to the inferior alveolar nerve with classical sagittal split osteotomy technique and proposed alternative surgical techniques using computer-assisted surgery. *Int J Oral Maxillofac Surg*, 41: 79 - 86.
- WOLFORD, L., RAFFERTY, C. 1987. Modification of the mandibular ramus sagittal split osteotomy. *Oral Surg Oral Med Oral Pathol*. 64: 146 - 155.
- YAMAMOTO, R., NAKAMURA, A., OHNO, K., MICHII, K. 2002. Relationship of the mandibular canal to the lateral cortex of the mandibular ramus as a factor in the development of neurosensory disturbance after bilateral sagittal split osteotomy. *J Oral Maxillofac Surg*, 60: 490 - 495.
- YAMAUCHI, K., TAKAHASHI, T., KANEUJI, T., NOGAMI, S., YAMAMOTO, N., MIYAMOTO, I., YAMASHITA, Y. 2012. Risk factors for neurosensory disturbance after bilateral sagittal split osteotomy based on position of mandibular canal and morphology of mandibular angle. *J Oral Maxillofac Surg*, 70: 401 - 406.
- YLIKONTIOLA, L., MOBERG, K., HUUMONEN, S., SOIKKONEN, K., OIKARINEN, K. 2002. Comparison of three radiographic methods used to locate the mandibular canal in the buccolingual direction before bilateral sagittal split osteotomy. *Oral Surg Oral Med Oral Pathol Oral Radiol Endod*. 93: 736 – 742.
- YLIKONTIOLA, L., KINNUNEN, J., OIKARINEN, K. 2000. Factors affecting neurosensory disturbance after mandibular bilateral sagittal split osteotomy. *J Oral Maxillofac Surg*, 58: 1234 - 1239.
- YOSHIDA, T., NAGAMINE, T., KOBAYASHI, T., MICHIMI, N., NAKAJIMA, T., SASAKURA, H., HANADA, K. 1989. Impairment of the inferior alveolar nerve after sagittal split osteotomy. *J Cranio-Max-Fac Surg*, 17: 271 - 278.
- YU, I., WONG, Y. 2008. Evaluation of mandibular anatomy related to sagittal split ramus osteotomy using 3-dimensional computed tomography scan images. *Int J Oral Maxillofac Surg*, 37: 521 - 528.

APPENDIX I

Data Capture Sheet

Case Nr :.....

Patient:..... Folder nr:.....

Age:

Medical History:

<b>WIDTH OF THE MARROW SPACE</b>	<b>DISTANCE (mm)</b>		
	<b>X</b>	<b>Y</b>	<b>Z</b>
Mandibular canal to Buccal cortical bone			
Mandibular canal to Lingual cortical bone			
Mandibular canal to Superior cortical bone			
Mandibular canal to Inferior cortical bone			
<b>SURGICAL DETAILS</b>	<b>TICK</b>		
IAN present in distal segment of the mandible			
IAN lying free			
IAN present in proximal segment of the mandible			

## APPENDIX II



UNIVERSITY of the  
WESTERN CAPE

Department of Maxillo-Facial and Oral Surgery  
Faculty of Dentistry and WHO Oral Health Collaborating Centre  
University of the Western Cape  
Cape Town

### Patient Information Letter

I, Dr Mark Meyer (currently a qualified dentist enrolled in a specialist training program), plan to conduct a clinical study and we will really like you to be part of the study. The main purpose of the study is to describe the position, during surgery, of the main nerve found within the mandible called the inferior alveolar nerve, and compares it with a modern X-ray type scan taken prior to surgery. These X-ray type scans are called a cone-beam computer tomography (CBCT). A CBCT is the new 3-Dimensional X-ray machine that is currently used in modern dental practices. These scans are much superior to the old type 2-Dimensional X-rays used in the past. The patient and the surgeon can now get a 3-Dimensional view of the main nerve within the jaw and also see the anatomy of the bones of the jaws. As discussed with you, the difficulty of the operation lies in the identification and handling of the nerve during surgery. We are nearly sure that the patient and the surgeon will benefit from this 3-Dimensional knowledge and this knowledge will help us reduce possible injury to the nerve during surgery. By participating in the study, you will help to supply evidence to possibly support our views.

The faculty has acquired such a CBCT scan and all patients undergoing difficult surgery of which your operation is one, will routinely receive such a scan. We are therefore not going to give you any extra radiation if you participate in the study.

Participating in the study is on a voluntary basis. You may withdraw from the study at any time. Participating in the study or refusing to participate will not harm or prejudice you in any way. Participating in the study will definitely benefit future patients. All information will be kept strictly confidential.

If there are any other queries that I cannot help you with, you are welcome to contact my supervisor:

Prof JA Morkel

Tel: 021 9373087 or [jamorkel@uwc.ac.za](mailto:jamorkel@uwc.ac.za)

Thanking you in anticipation.

Dr Mark Meyer (Researcher)  
Registrar (Maxillo-Facial and Oral Surgery)  
Department of Maxillo-Facial and Oral Surgery, Oral Health Centre Tygerberg  
Contact details: Tel: (021) 9373119  
Mobile: 0714911896

I, (Patient name) ....., fully understand the information supplied to me by Dr Mark Meyer in the above information letter.

Signature: .....Date: .....



## APPENDIX III



UNIVERSITY of the  
WESTERN CAPE

Department of Maxillo-Facial and Oral Surgery  
Faculty of Dentistry and WHO Oral Health Collaborating Centre  
University of the Western Cape  
Cape Town

### Consent form

I, Mr/Mrs/Miss .....

Date of Birth: ..... File no./Hosp. Sticker .....

Am willing to participate in the study as describe to me in the patient information letter by Dr Mark Meyer. I understand that participation in the study is voluntary.

The study is approved by the Ethical and Research Committee of the University of the Western Cape and participation in this study is on a voluntary basis. I have been adequately informed about the objectives of the study. I also know that I have the right to withdraw from the study at any stage which will not prejudice me in any way regarding future treatments. My rights will be protected and all my details will be kept confidential. No personal information will be published.

I hereby consent to be part of the research/study.

Patient's/patient's parent or guardian's name: .....

Patient's/patient's parent or guardian signature: .....

Witness name: .....

Witness signature: .....

Researcher's signature: .....

Dr Mark Meyer

Date: .....