

Forensic dentistry case book 3: Supplemental chrome cobalt partial denture used in identification of burned remains

SADJ June 2015, Vol 70 no 5 p220 - p221

V M Phillips¹, S Chandler²

CASE REPORT

An adult female was involved in a motor vehicle accident on one of the major highways of Cape Town in the early hours of the morning. The car caught fire and the body was burned beyond recognition. The charred remains were taken to the Salt River Medico-legal Laboratory, where an autopsy was undertaken to establish the cause of death. The hands were severely burned so that finger prints were impossible to use for identification. An oral autopsy had to be performed in order to gain access to the teeth. The maxilla was found to be fractured from the skull base and the mandible had a fracture in the midline between the lower left and right central incisor teeth (31 and 41). Upper and lower chrome cobalt partial dentures were found *in situ*.

Dental radiographs were taken of the upper and lower teeth. Photographs of the upper and lower chrome cobalt dentures *in situ* were taken to illustrate the relationship of the denture and the replacement teeth. A post mortem dental record was compiled that recorded the dental formula of the victim and the dental restorations as well as the upper and lower chrome cobalt partial dentures.

The registration number of the vehicle was used to establish ownership and possibly the identification of the victim. Ante-mortem dental records were obtained of the victim (JM). The data within these records, however, were inadequate for dental identification purposes.

1. **V M Phillips:** BDS, MChD, Dip. Max-Facial Radiol, FC Path SA (Oral Path), PhD, D.Sc. Department Oral and Maxillofacial Pathology & Forensic Sciences, Faculty of Health Sciences, University of the Western Cape.
2. **S Chandler:** BChD, MSc. Department Oral and Maxillofacial Pathology & Forensic Sciences, Faculty of Health Sciences, University of the Western Cape.

Corresponding author

V M Phillips:

Department Oral and Maxillofacial Pathology & Forensic Sciences, Faculty of Health Sciences, University of the Western Cape, South Africa.
Tel: 021 937 3161. E-mail: vmphillips@uwc.ac.za

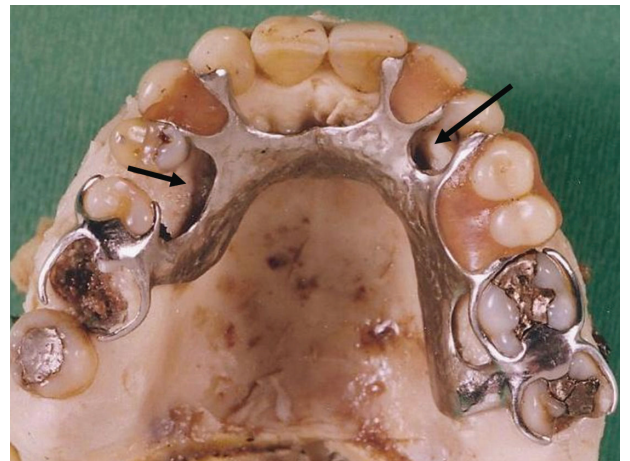


Figure 1: The upper chrome cobalt partial denture found in the victim's mouth during autopsy. Note the ill-fitting palatal aspect of the denture (arrows)

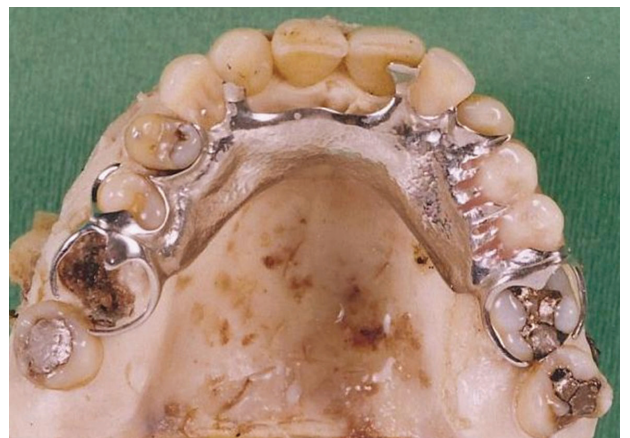

Figure 2: The newer upper chrome cobalt partial denture supplied by the victim's husband.

During the examination of the victim's dental data it became obvious that the chrome cobalt denture was old and did not fit the palate accurately (Figure 1). The author VMP subsequently contacted the victim's husband with regard to further dental information. The husband was questioned as to whether the victim had recently had a

newer denture made. The answer was positive and he subsequently found a second chrome cobalt denture amongst her possessions.

The new chrome cobalt denture was fitted to the victim's upper jaw and was found to fit perfectly, thus making a positive identification of (JM).

DISCUSSION

A chrome cobalt partial denture is designed and cast to accurately fit all the palatal contours, rotations and embrasures of the teeth. Ring clasps that accurately fit around the teeth are added to help retain the denture in the mouth. Metal rests are also placed on the denture that fit onto the palatal and occlusal surfaces of the teeth. This enables the denture to withstand the biting forces from the opposing teeth. The surfaces on the teeth that support these metal rests are often modified in order to prevent interference during the normal occlusion of the teeth. These features of chrome cobalt partial dentures make them unique in the identification process of unknown remains. The maxillary teeth of this victim had an unusual dental formula. The maxillary lateral incisors (teeth 12 and 22) were missing and the maxillary right canine (tooth 13) had possibly been moved orthodontically into the position of the missing right maxillary lateral incisor (tooth 12). This resulted in a space between the relocated right maxillary canine and right maxillary 1st premolar (teeth 13 and 14). This space was filled by a tooth on the upper chrome cobalt partial dentures (both the denture found at autopsy and the supplemental denture presented with this feature). The supplemental upper chrome cobalt partial denture fitted the mouth of the remains with an impressive degree of accuracy, which led to the positive dental identification of the victim.

This case was quite extraordinary; a positive dental identification would not have been possible had the second upper chrome cobalt partial denture not been found.

During the manufacture of a chrome cobalt denture plaster of Paris models are cast. The dental laboratories usually cast several different models during the manufacturing process of chrome cobalt dentures.^{1,2,3} The primary models, which are used to manufacture the special trays, are usually not damaged or broken, but are discarded by the laboratories. Instead, this model could be returned to the dentist and then either stored by the dentist, or given to the patient for safe keeping. The teeth are usually modified (by the cutting of occlusal rests or build-up of undercuts on teeth) before the final impression is taken (using the special tray). As a result, the primary model will not be an absolutely accurate replica of the patient's teeth, but it may still be of great assistance in the identification process in those cases where no other dental information is available.

CONCLUSION

The victim in this case was positively identified by the comparison of two upper chrome cobalt partial dentures. Dental identification would not have been possible had the victim's husband failed to submit the second upper chrome cobalt partial denture.

It may be an option to give one of the models used in the manufacturing of chrome cobalt partial dentures to the patient for safe keeping. This model may prove to be great value in the dental identification process.

Declaration: No conflict of interest declared.

References

1. Sowter J.B. Removable Prosthodontic Techniques (Dental Laboratory Technology Manuals). Revised Edition. The University of North Carolina Press, 1986.
2. Osborne J. and Lammie G.A. Partial Dentures. 4th Ed. New York. Blackwell Scientific Publications, 1974.
3. Hudis M.M. Dental Laboratory Prosthodontics. Philadelphia: W.B. Saunders, 1977.